

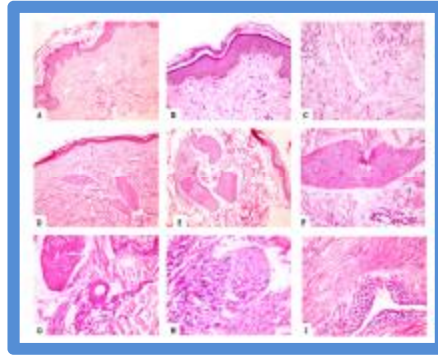Figure (1): H&E stained tissue sections showing histological differences between cirrhotic patients with and without pruritus. **A-B:** Non-pruritus skin (A 100x) (B 200x) , **C-D-E-F-G-H-I:** Pruritus skin with: vascular ectasia (C) (400x), hypertrophied Nerves (**D-E-F**) (D 100x, E 200x, F400x), inflammatory cells around the nerves (**H** 400x) and lymphocytic vasculopathy (**I** 400x)

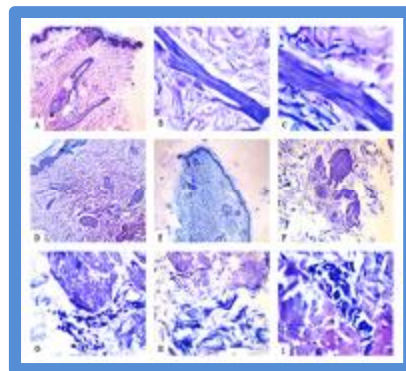


Figure (2): Mast cells (Geimsa stain)

A-I: Hypertrophied nerves in pruritus group with some Mast cells around them as well as in perivascular distribution.(A 100x, B 200x, C 400x, D 100x, E,F 200x, G, H, I 400x)