

(34.29%), while hypertension constituted (8.57%) and other systemic diseases 6 (17.14%).




Fig. (1): demonstrates

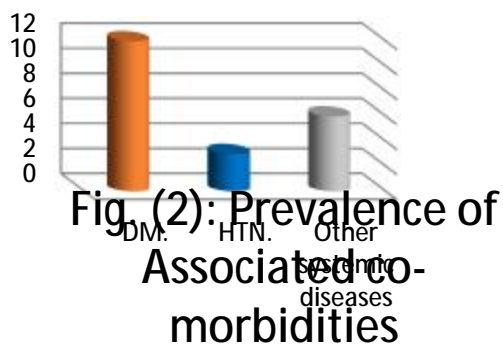
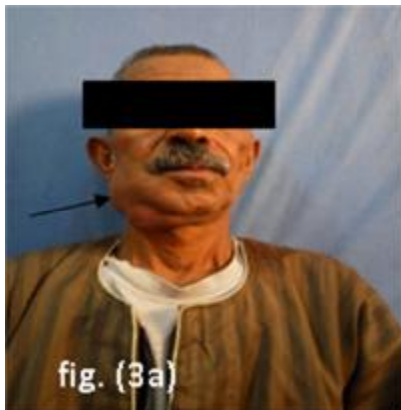

Fig. (2): Prevalence of Associated comorbidities

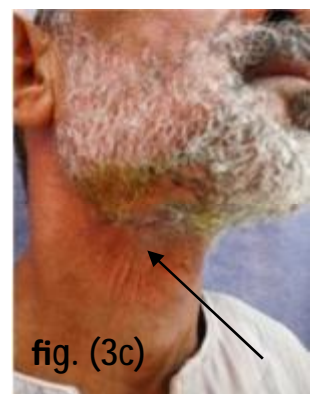
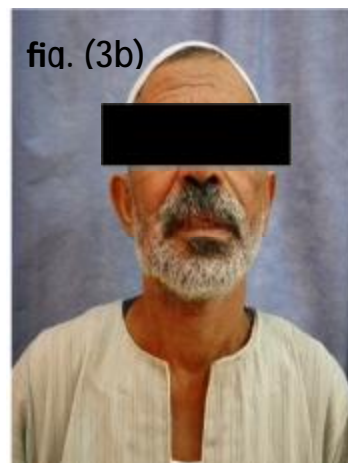
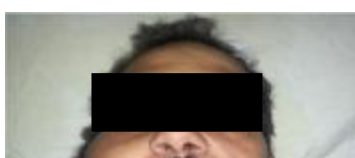

Fig. (3a) Male patient, 65yrs., diabetic, Presented with RT. Submandibular space infection (arrow).

Fig. (3d, c) see the same patient post-operative after drainage of the abscess (arrow). (fourth week of follow up).

Fig. (4) Female patient, 40yrs., diabetic, show sever form of trismus (about 0.5 cm.).


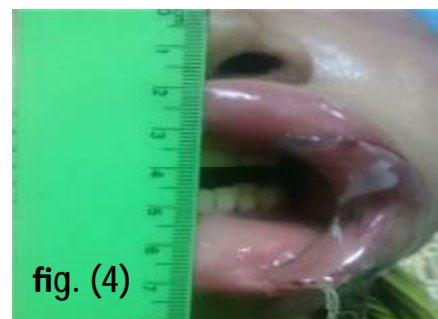
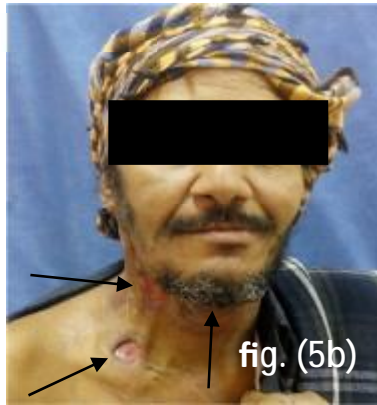



Fig. (5a) Male patient, 50yrs., diabetic, Presented with RT. Submandibular, submental, masseteric and supraclavicular space neck infections (arrows).

Fig. (5d, c) see the same patient post-operative after drainage of the abscess (arrows). (third week of follow up).