

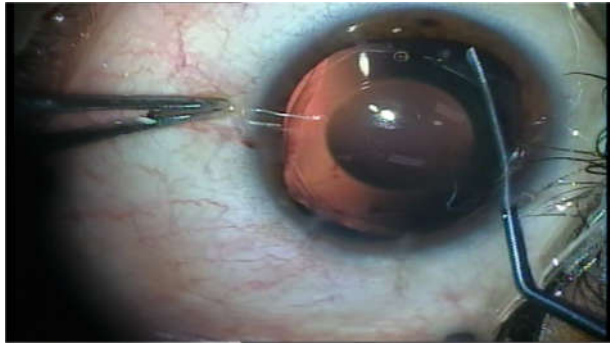Figure (1) shows the implantation of The ICL below the iris

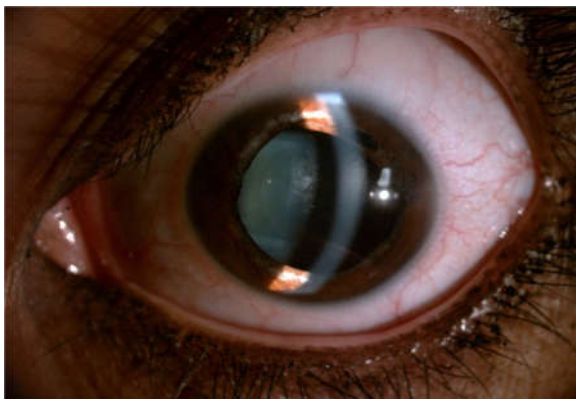


Figure (2) shows anterior subcapsular cataract after ICL