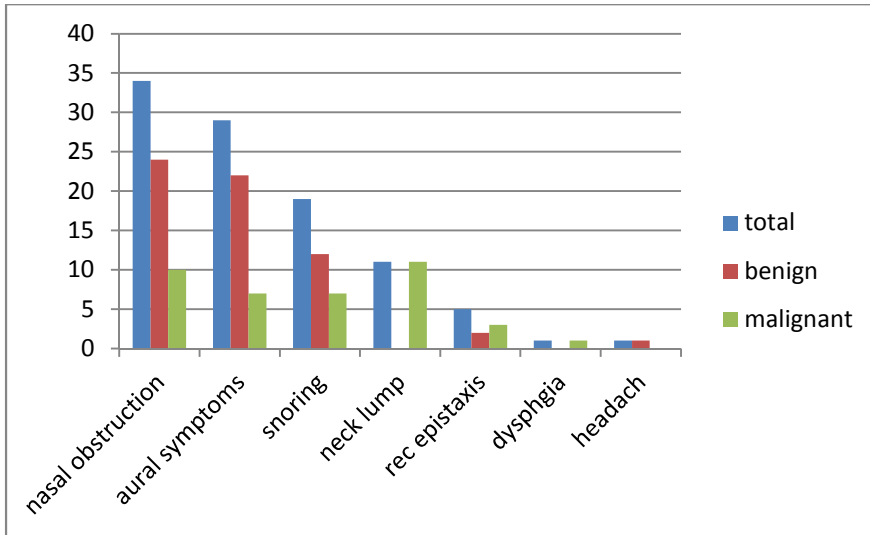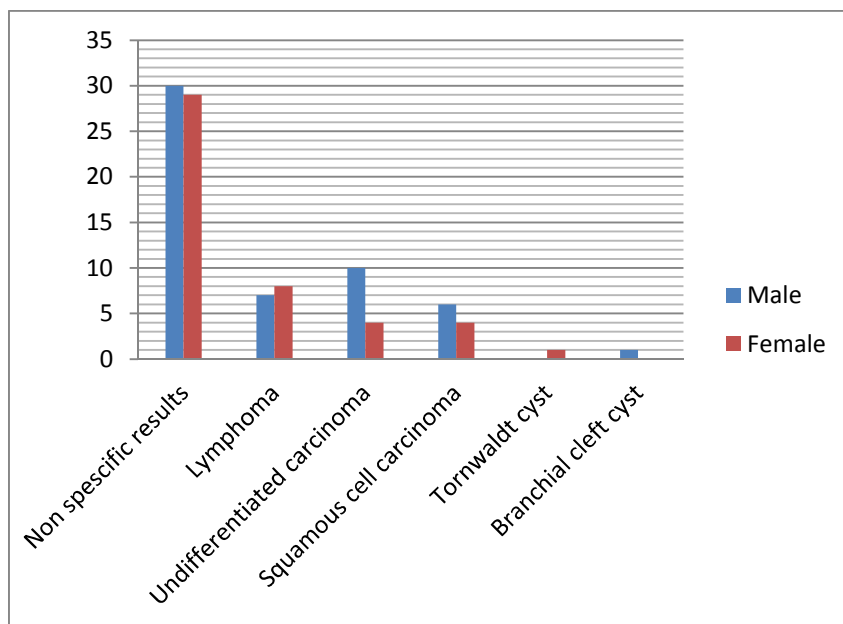


**Figure 1: Distribution of the presenting symptoms in adult patients with nasopharyngeal mass.**



**Figure 2: Different pathological lesions encountered in adult nasopharynx and difference in prevalence between both sexes.**