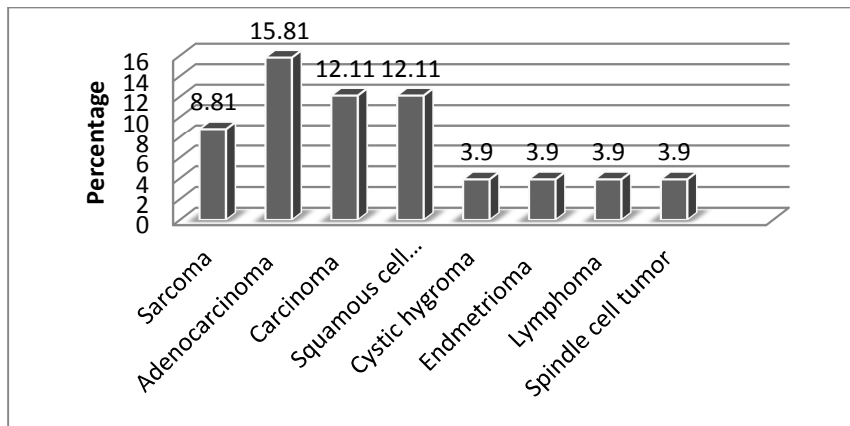
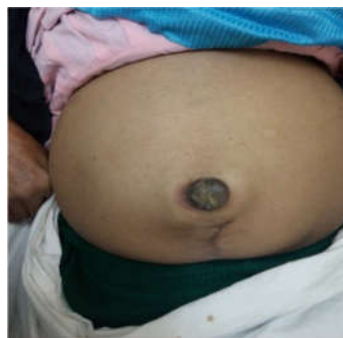
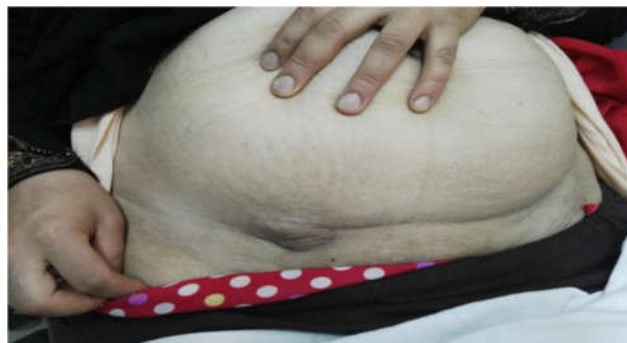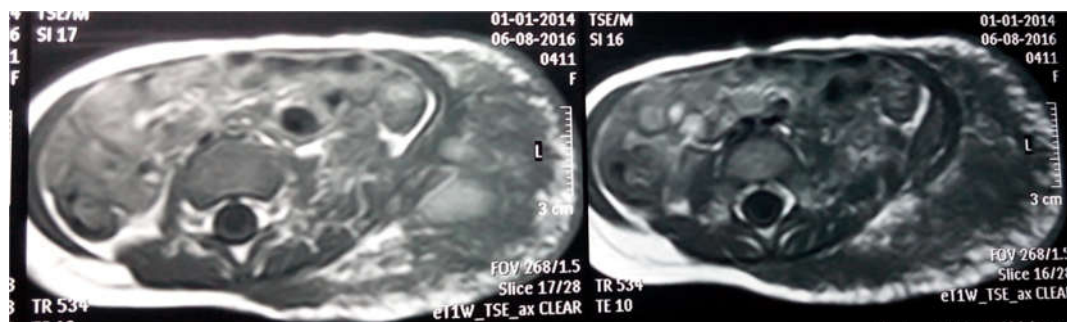
**Figure (1):** Bar chart showing Distribution of studied population by biopsy results.



**Fig (2):** female patient 60 years with umbilical mass (Sister Josef nodules)



**Fig (3):** female patient 45 years with endometrioma at site of a previous cesarian section



**Fig (4):** MRI image showing lipolymphangioma at the anterior abdominal wall