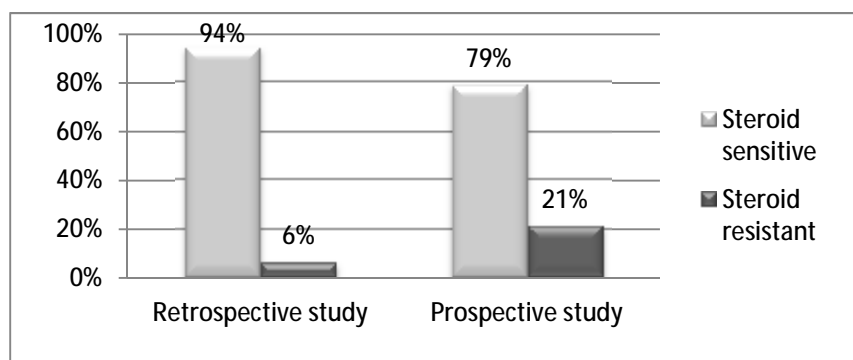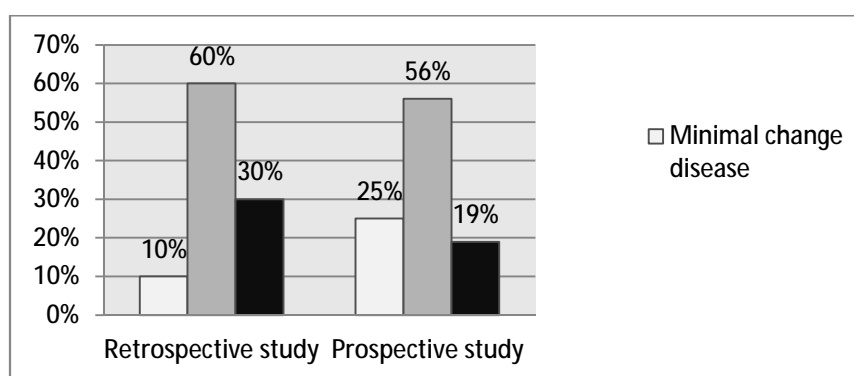


**Figure (1): Steroid response in retrospective and prospective studies**



**Figure (2): Histopathological spectrum in biopsied steroid resistant patients**

There were changes in the steroid response pattern within the same histopathological types in the prospective study relative to the retrospective study as shown in table (5)