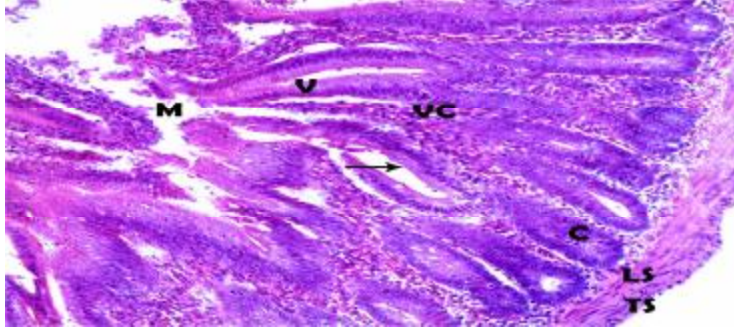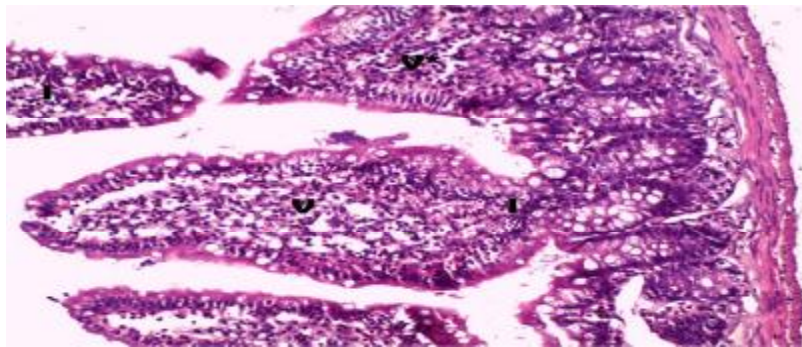
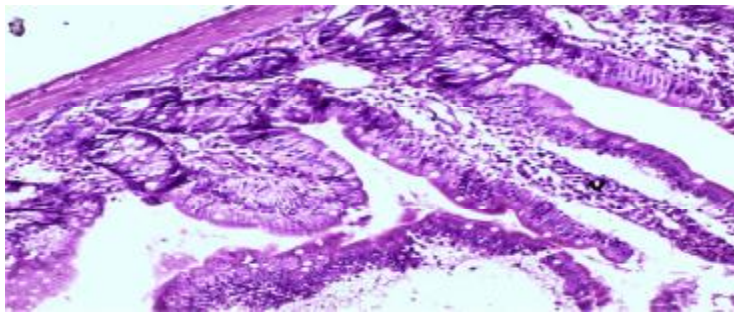


**Fig. 1) :** A photomicrograph of a transverse section of a jejunum of adult control animal (V), villus core (VC) ,brush border of enterocytes (arrow) ,the intestinal glands showing; villi (C),circular muscles (LS) longitudinal muscle (TS).  
(H&EX200)



**Fig.2):** A photomicrograph of a transverse section of a jejunum (**group IIa**), showing shortening (V\*) and broadening of villi (V) slight inflammatory cell infiltrations(I).  
(H&E.X200)



**Fig.3):** A photomicrograph of a transverse section of a jejunum (**group IIb** ), showing the intestinal villi with some villi height restoration (v), and less inflammatory cell infiltrations compared to group IIa.  
(H&E. X200)