

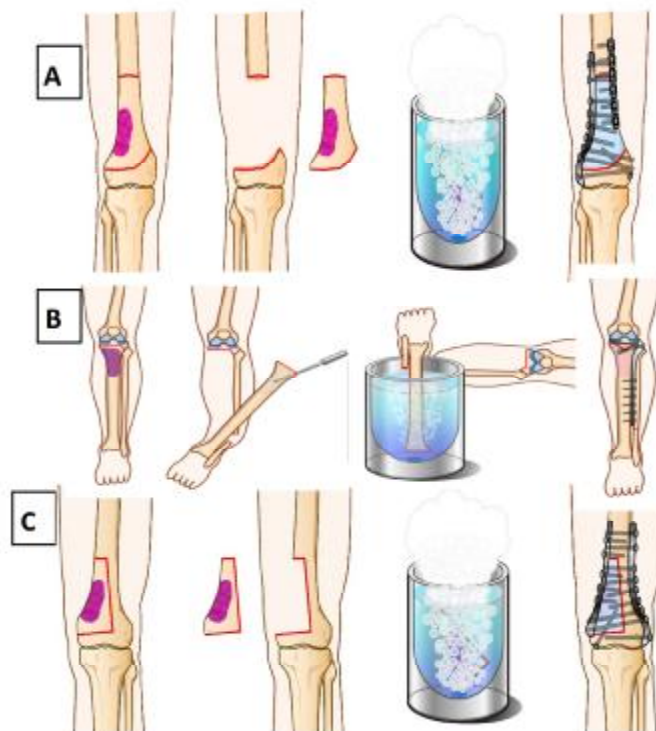Figure 1

A: Free freezing

B: Pedicle freezing

C: Hemicortical freezing

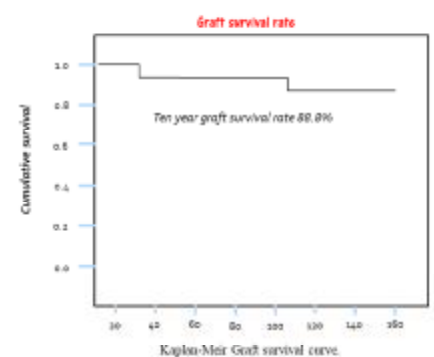
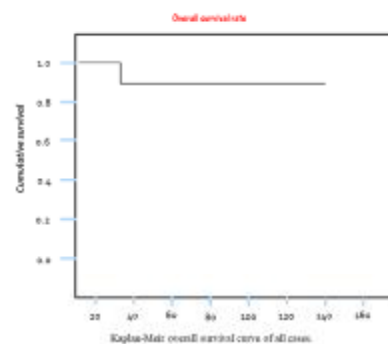


Figure 2. A: Kaplan Meyer overall survival rate, B: Kaplan Meyer graft survival rate

Figure 3: Case presentation representing a ten years old boy at time of surgery with osteosarcoma distal right femur. **A,B:** Anteroposterior and lateral view of distal femur XP showing the tumor mass. **C:** T2 weighed MRI image of the distal femur showing the tumor mass with high signal intensity. **D:** Intraoperative XP showing the freely resected segment to be frozen, and the host bone. **E:** Intraoperative photo of free freezing. **F:** The tumor bearing bone after freezing. **G:** The frozen segment after repositioning and fixation. **H:** Post-operative XP of the distal femur after freezing and fixation. **I:** Long leg film showing the LLD of 3 cm. **J,K:** Clinical photo of the knee in full flexion and full extension.

