

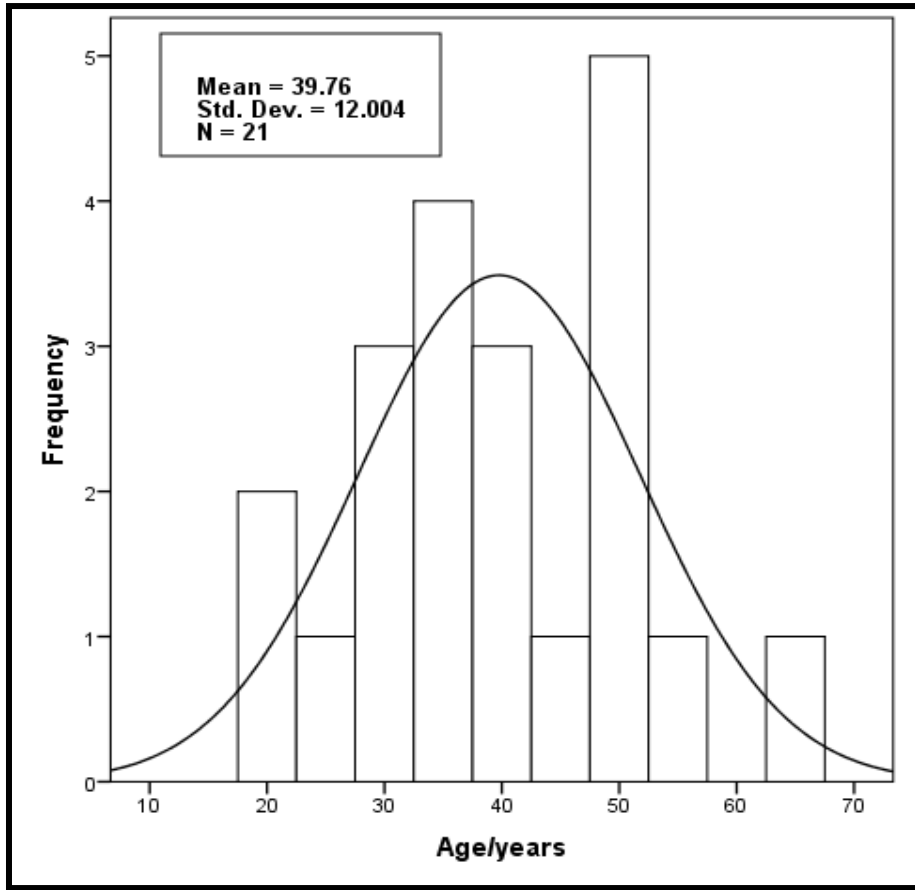Fig. 1: Age Frequency of studied sample.

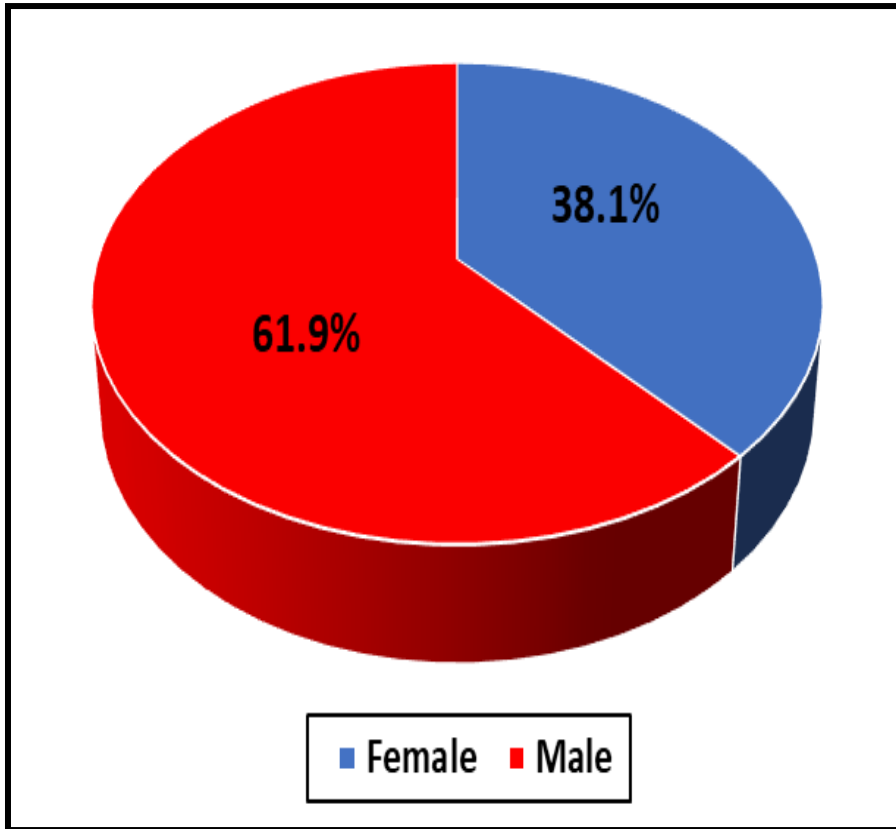


Fig. 2: Sex Distribution of studied patients.

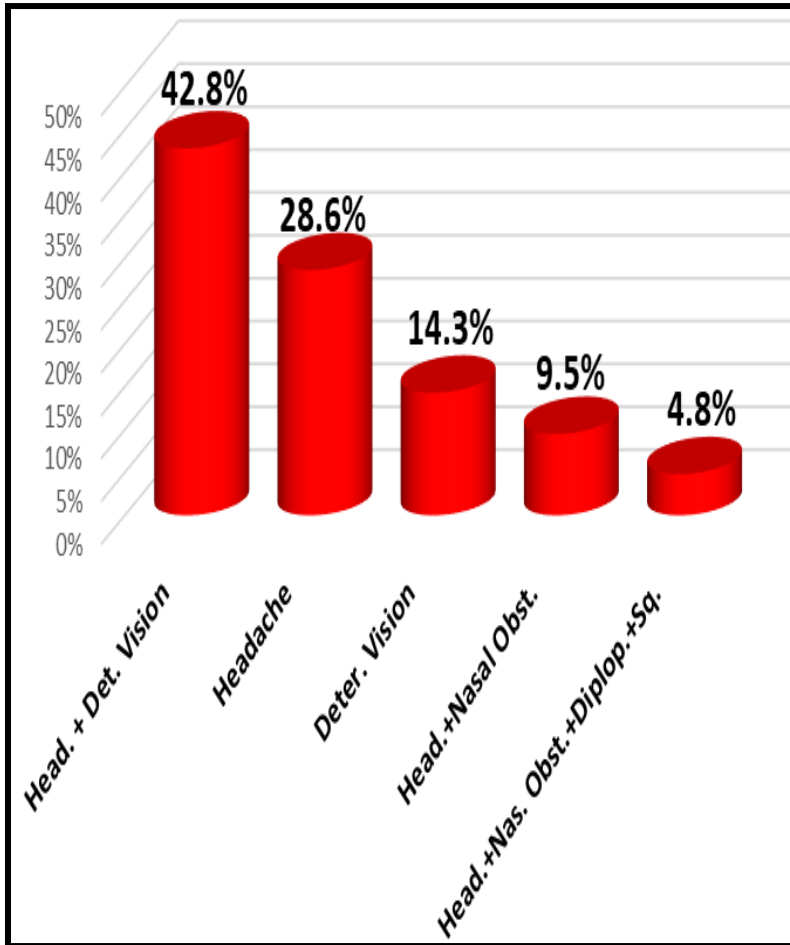


Fig. 3: Distribution according to pre-operative clinical presentation.

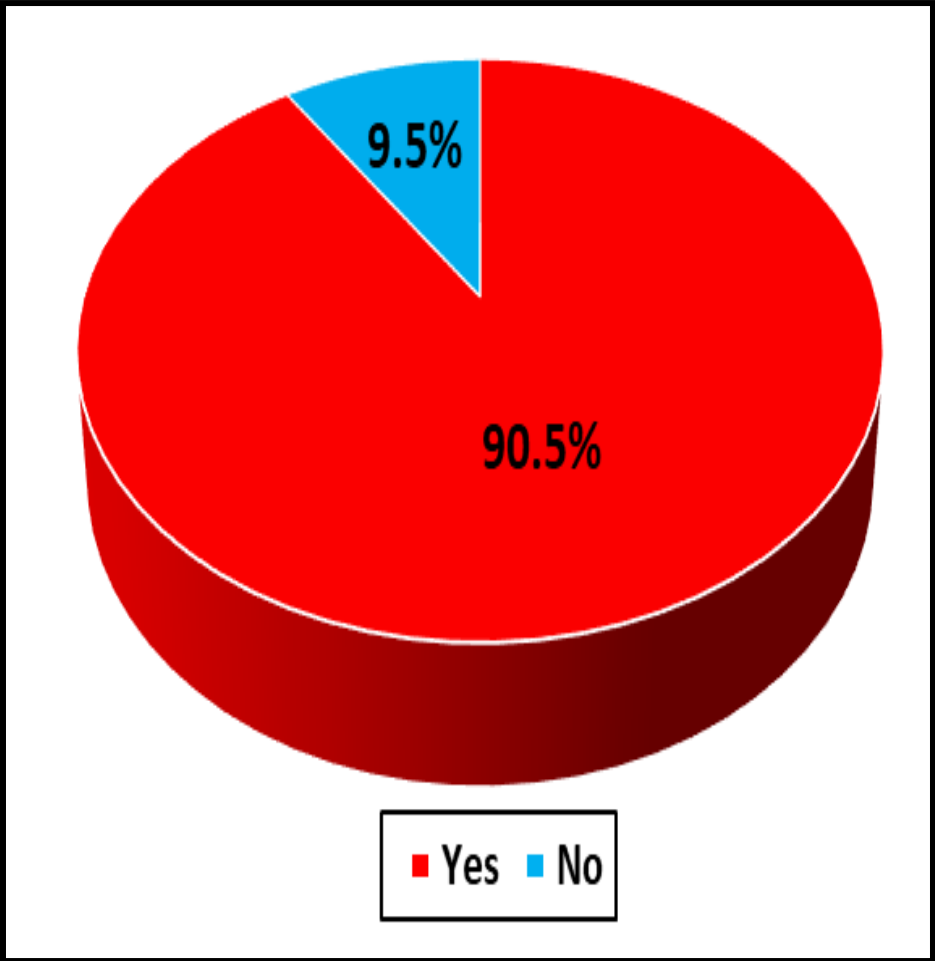


Fig. 4: Rate of postoperative improvement of symptoms.

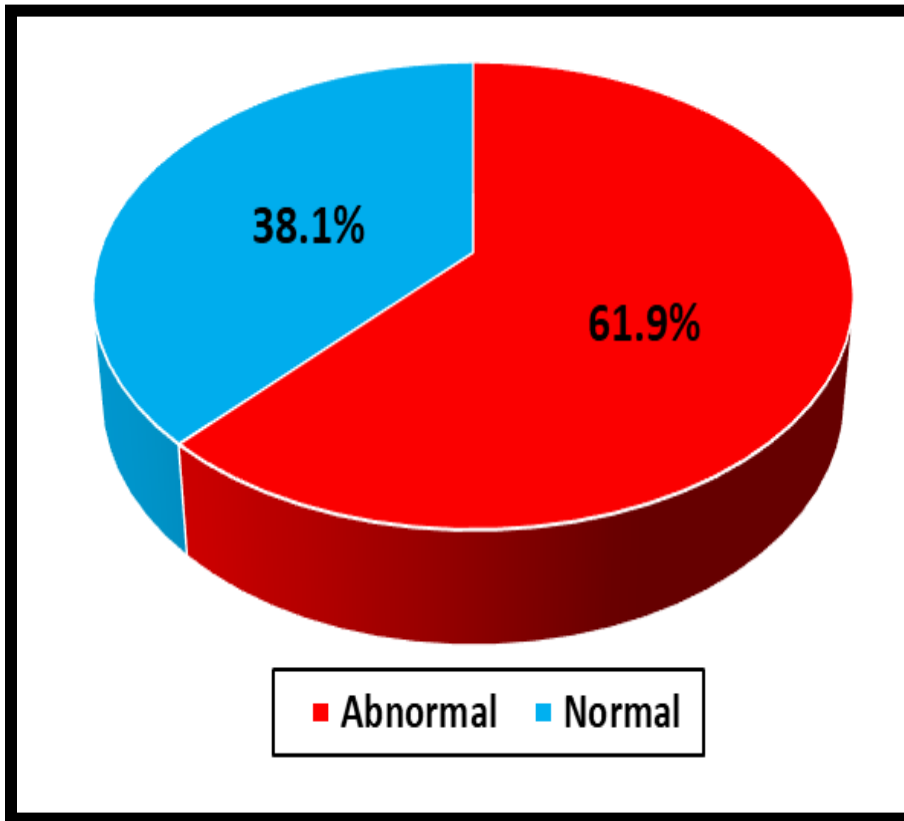


Fig. 5: Distribution according to pre-operative ophthalmological evaluation.

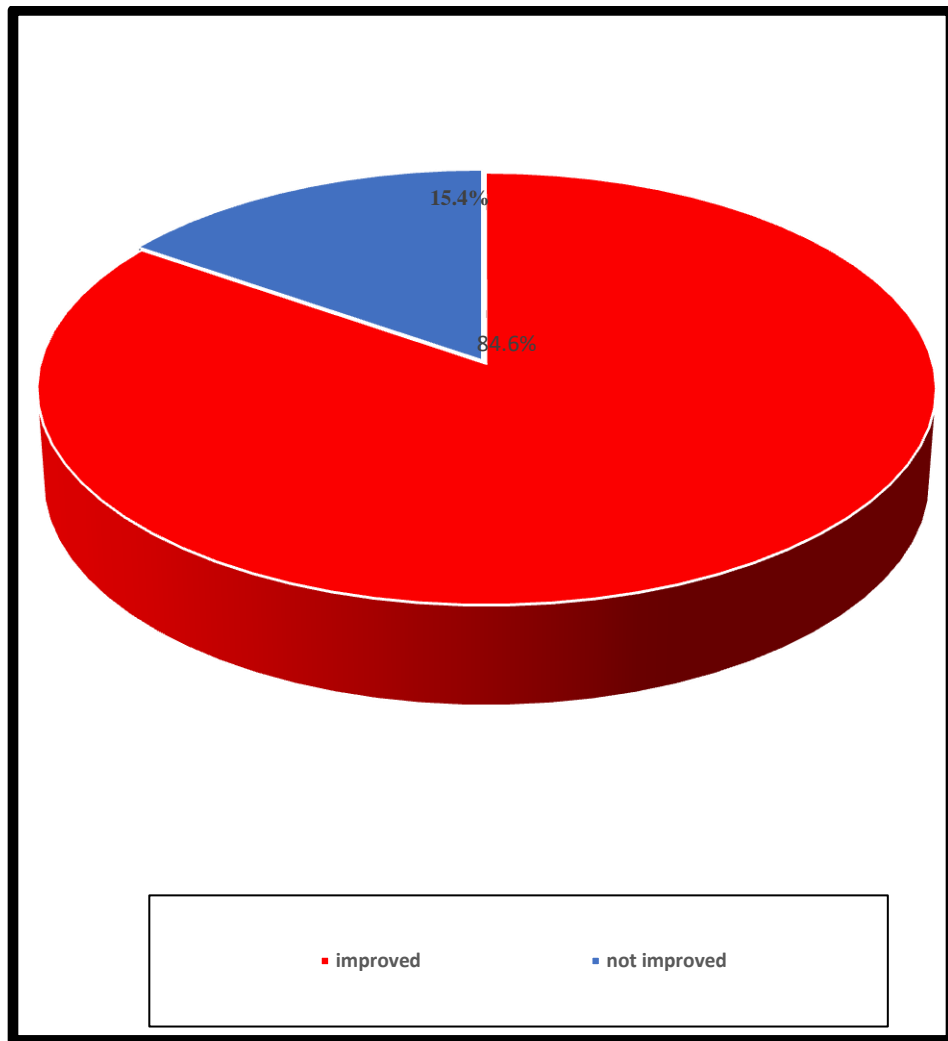


Fig. 6: Rate of postoperative improvement of vision.

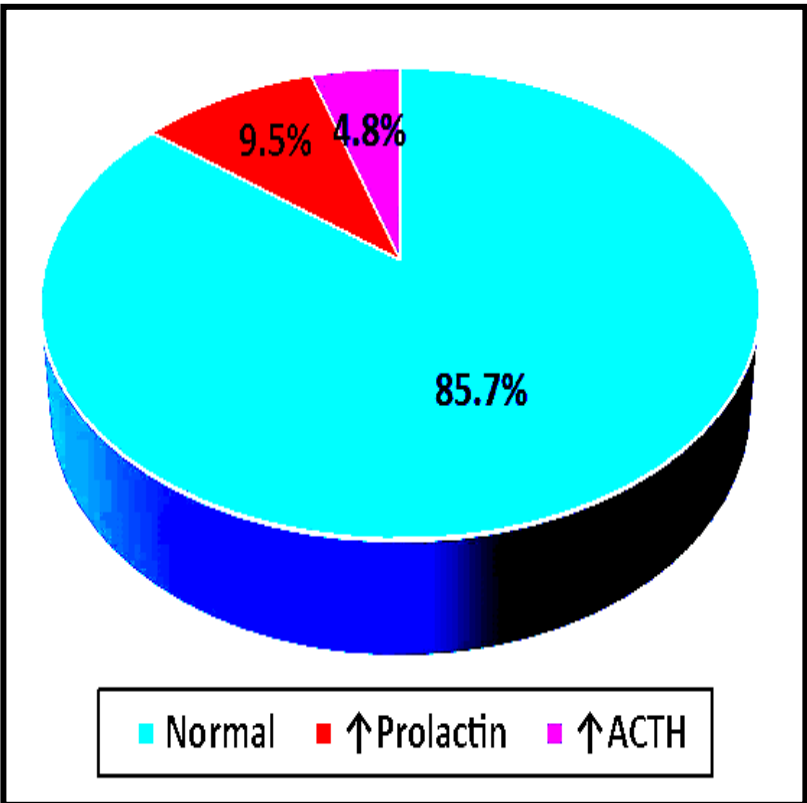


Fig. 7: Distribution according to pre-operative hormonal evaluation.

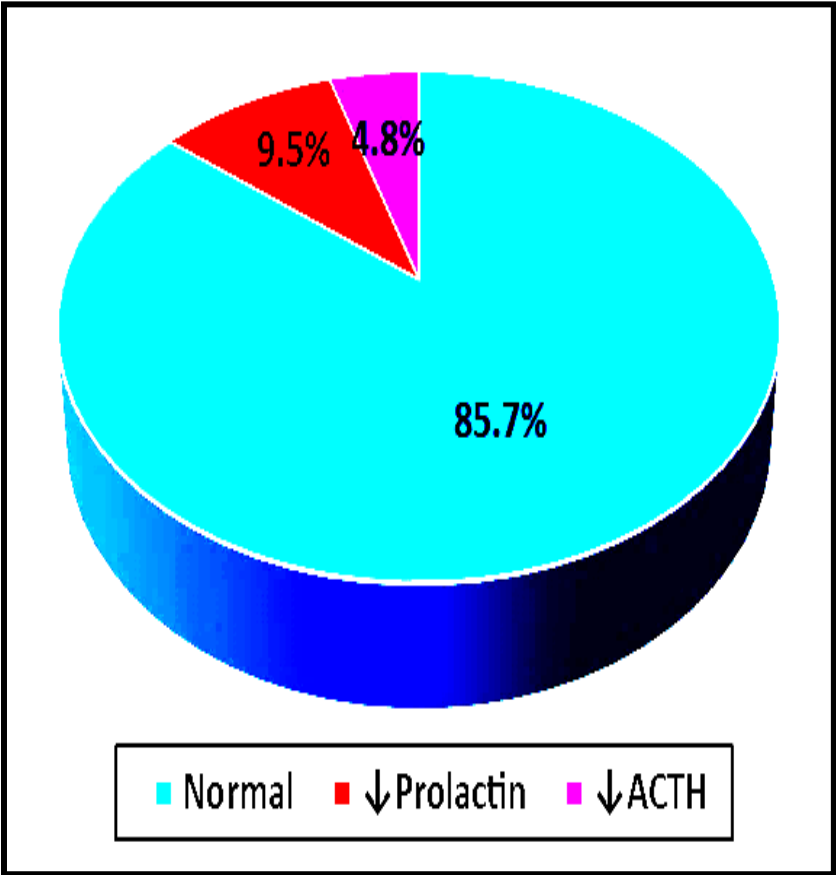


Fig. 8: Rate of postoperative improvement of hormonal level.

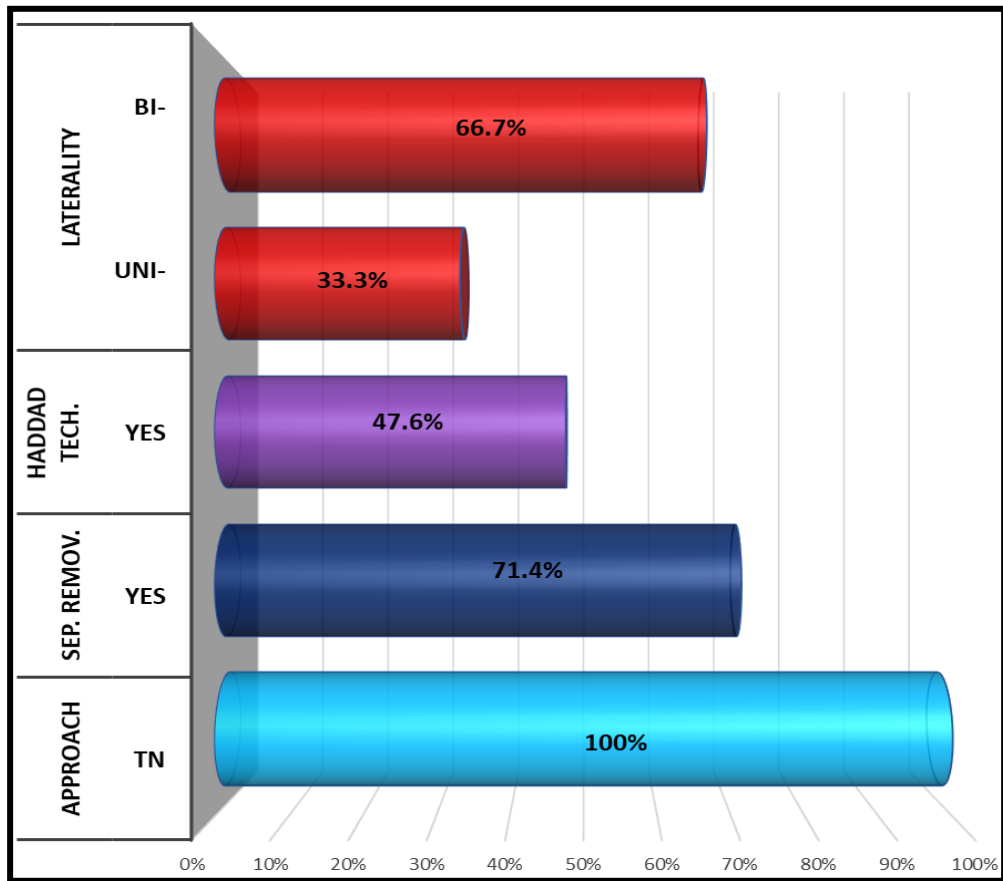


Fig. 9: Surgical Data of the Studied patients.

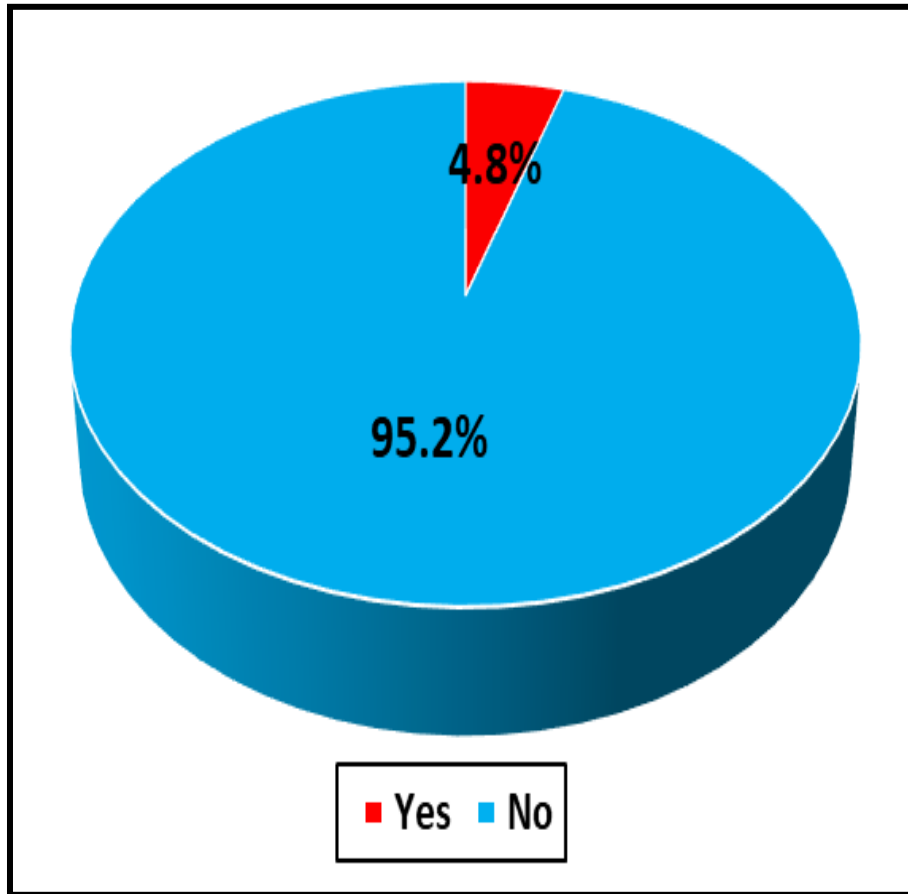


Fig. 10: Postoperative Complications of the Studied patients.

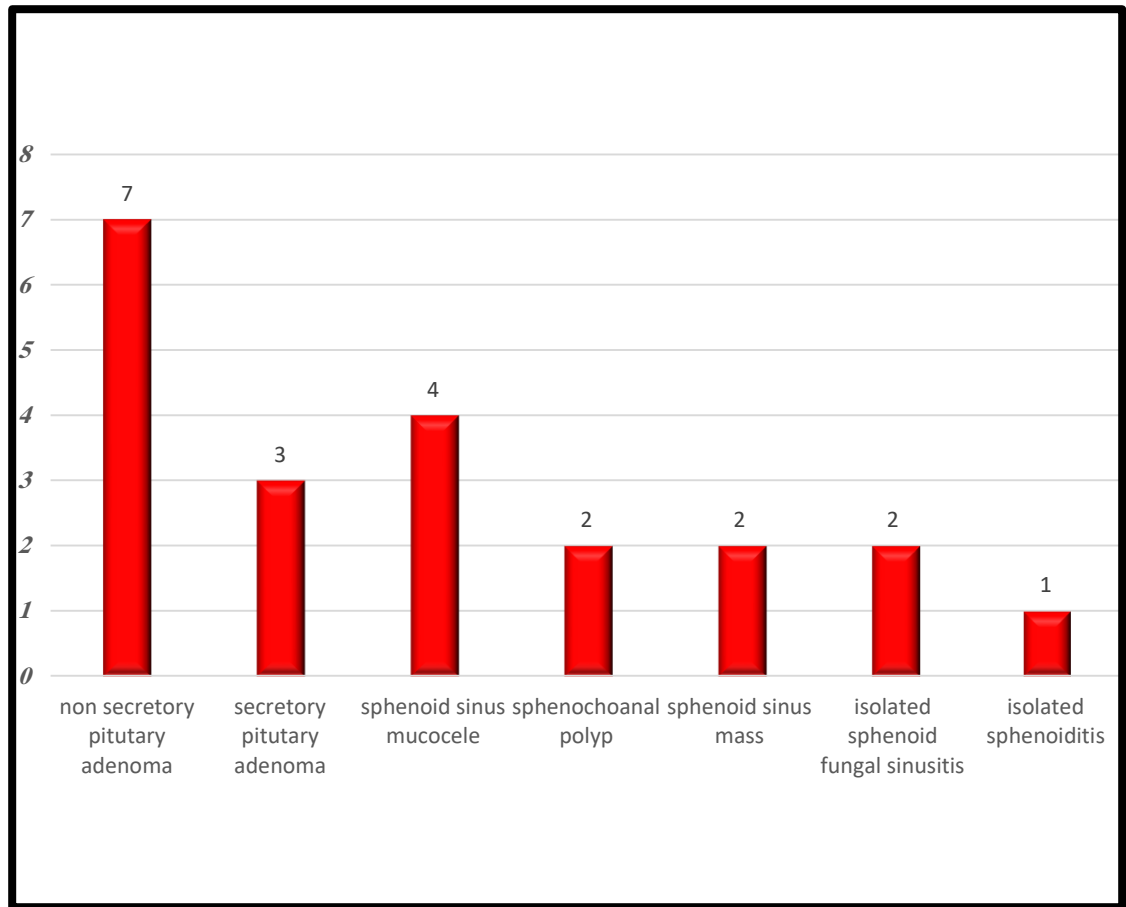


Fig. 11: postoperative histopathology of the Studied patients.

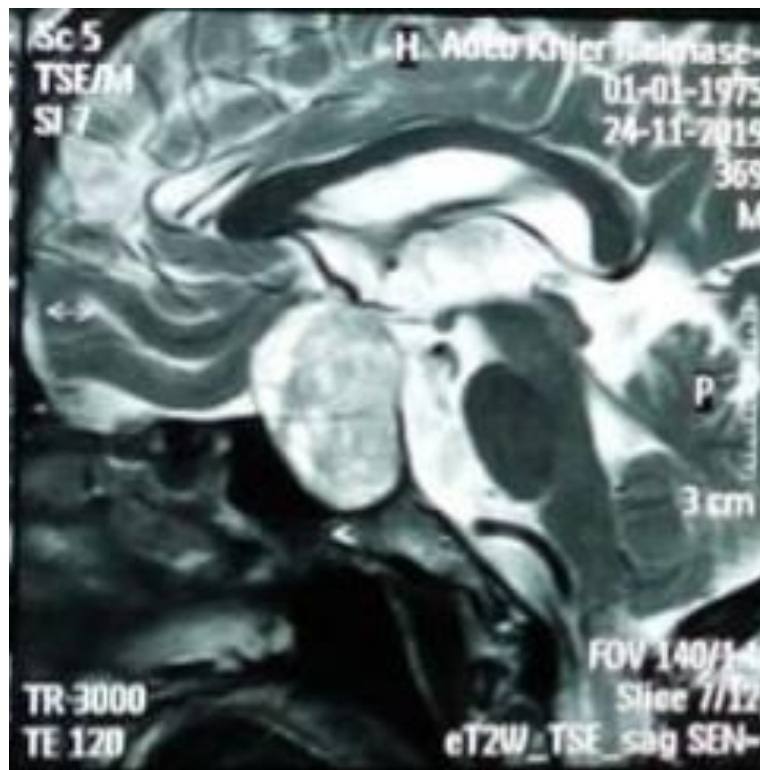
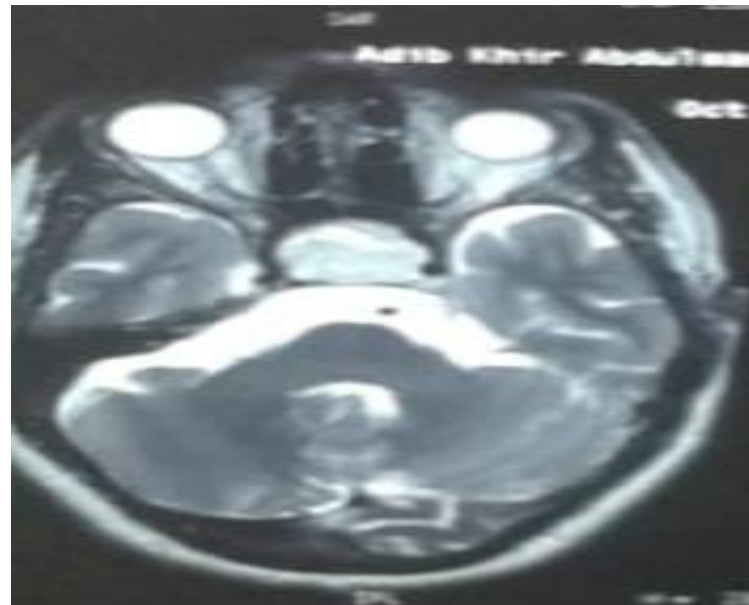


Fig. 12: M.R.I brain showing pituitary adenoma

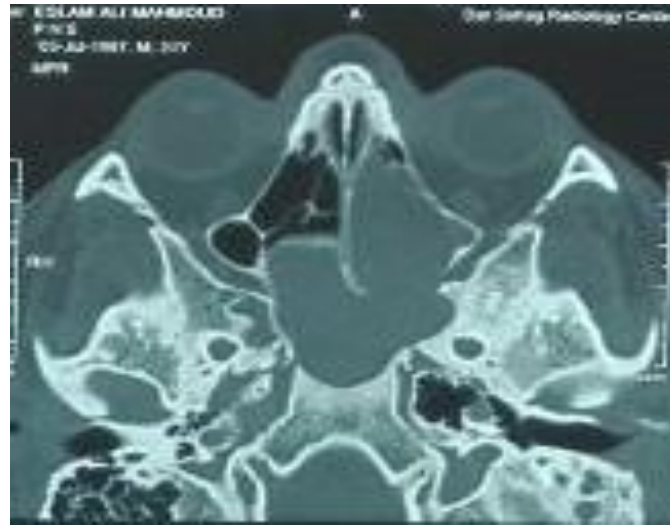
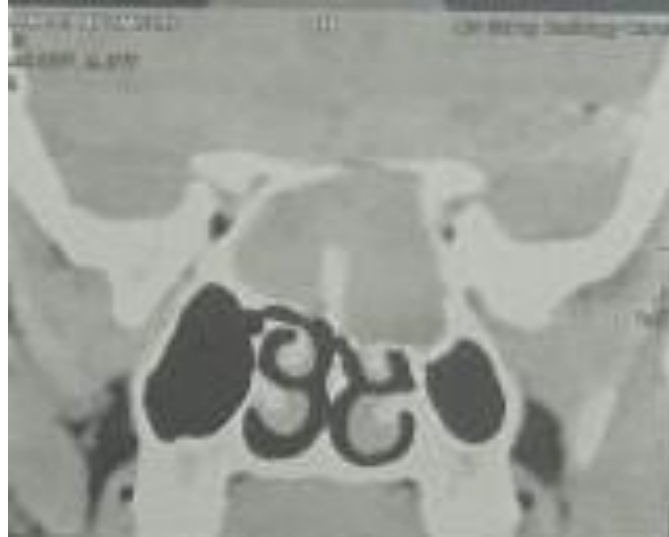

Fig. 13: C.T nose and paranasal sinuses showing left sphenoid sinus mucocele.

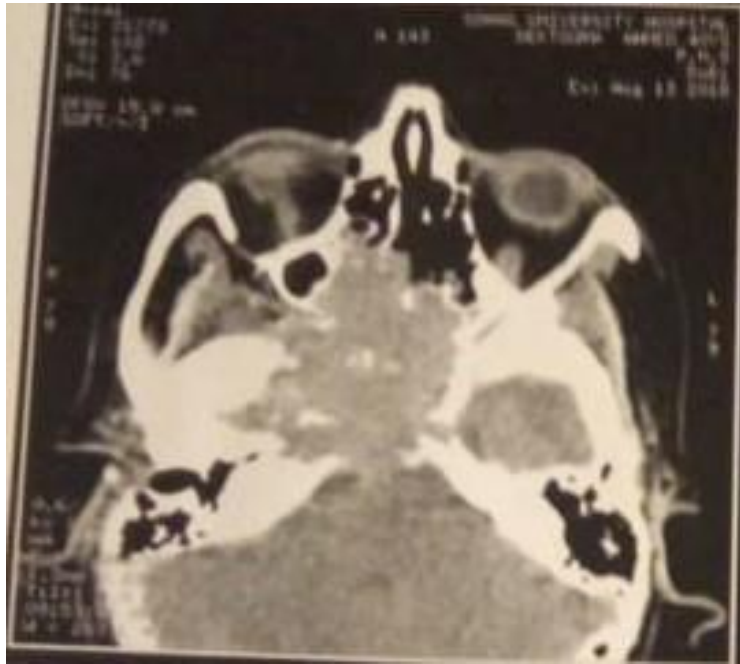
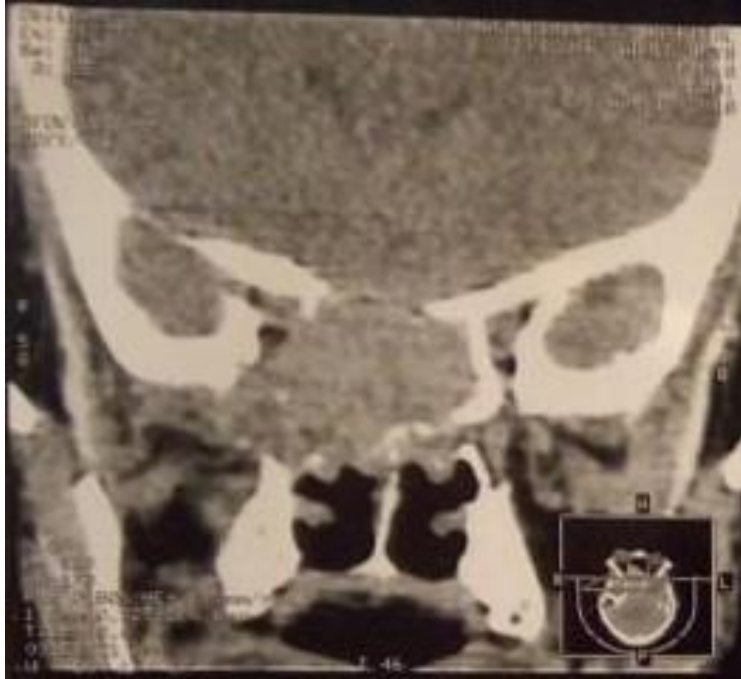
Fig. 14: C.T nose and paranasal sinus showing isolated sphenoid sinus fungal sinusitis.

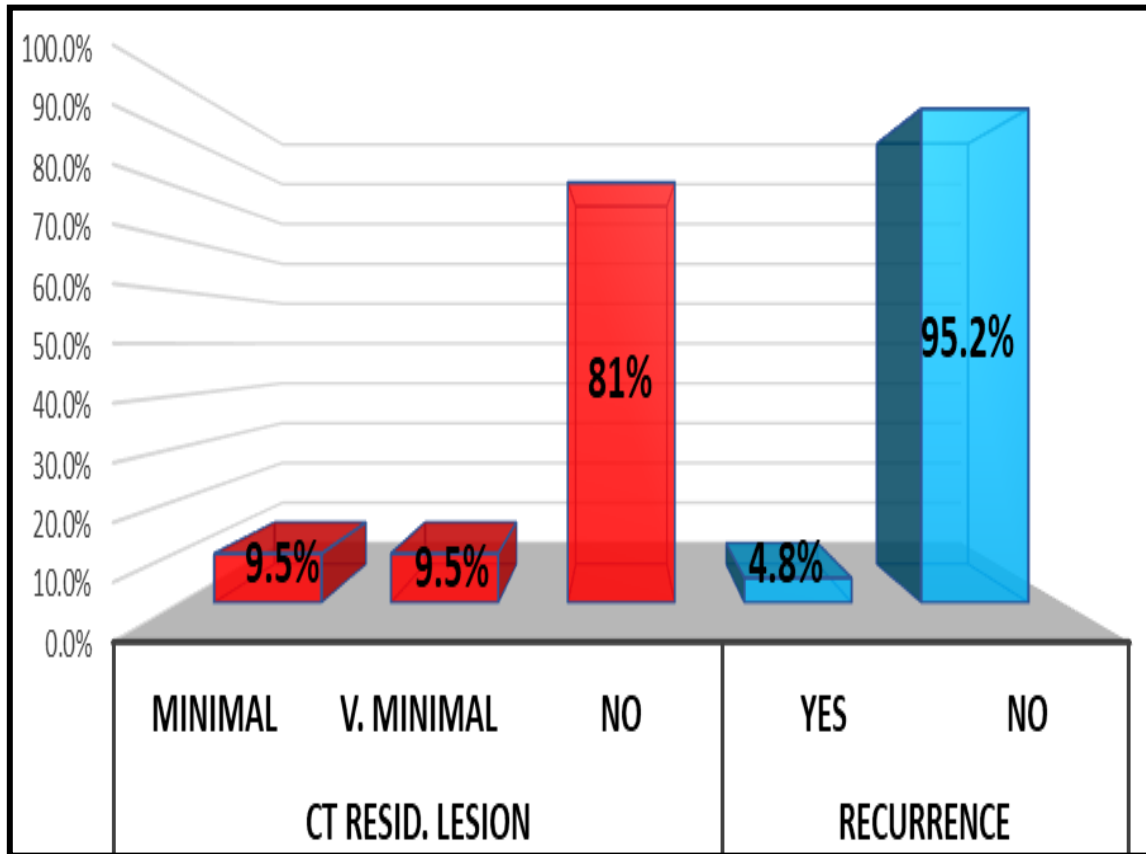


Fig. 15: Postoperative radiological evaluation and follow-up of the studied patients.