

**Figure 1**

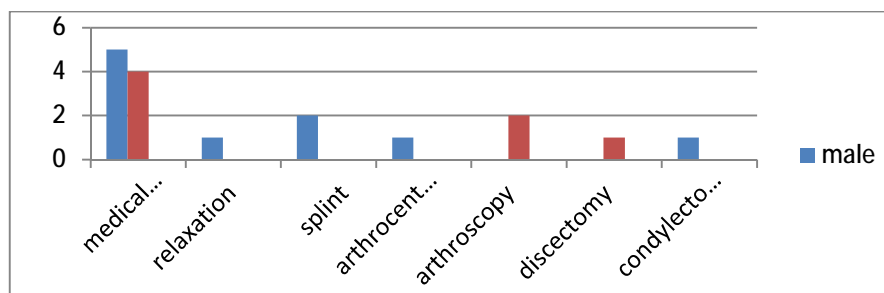
Modalities of treatment chart

**Figure 2**

Sixteen years old female patient with pain and click on the Lt TMJ, arthroscopy was done.

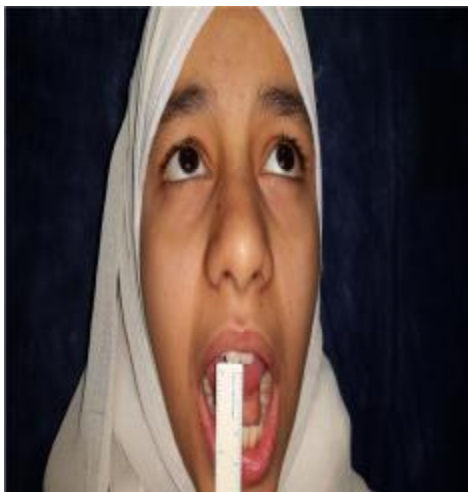A, the patient preoperative, B; the patient is postoperative,  
Treatments modalities

**Figure 1**

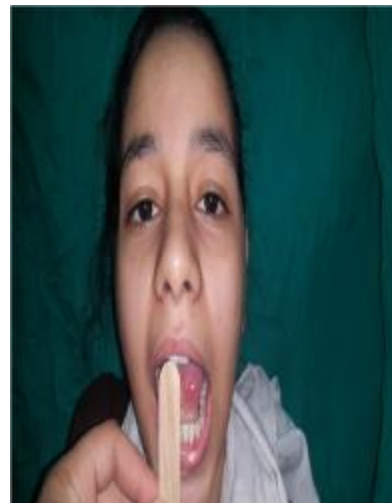

**Figure 2**

**A**



**B**



**Figure 3**

**A**



**B**

