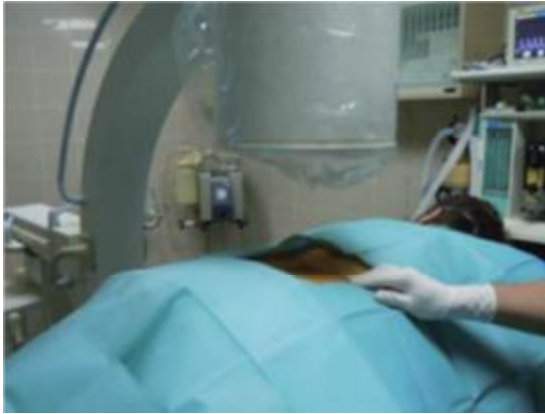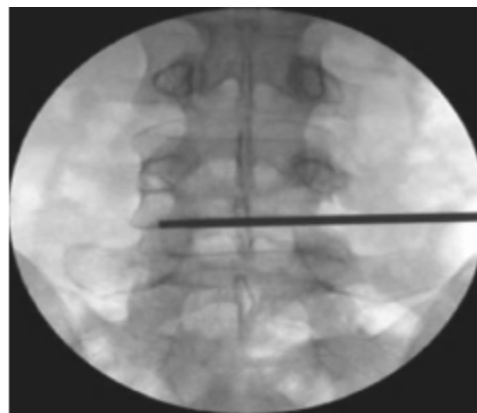




, and

(a)



(b)

Figure (1): (a,b) Mark the level of entry for lumbar transforaminal block.

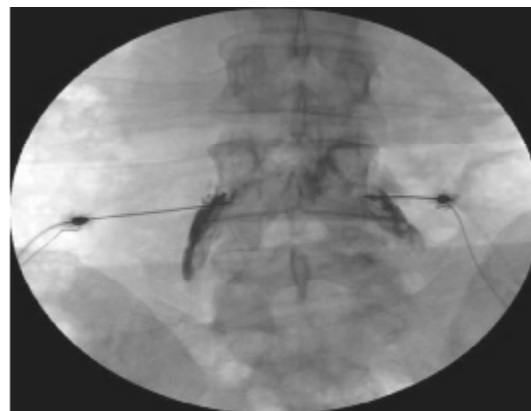


Figure (9): Bilateral transforaminal injection due to bilateral inflammation.