

Virtual CT Colonography Versus Lower Endoscopy in Detection of Colorectal Lesions.

Hossam Saro M.Sc., Khaled Fawzy MD, Mohammed Alaa MD, Mohammed Zaki Ali MD, Wael Barakat MD.

Abstract

Background

Colorectal cancer is the third most common cancer and the second leading cause of cancer-related death in Western countries. As with other malignancies, screening and early detection is fundamental for successful management of colorectal cancer. Computed tomographic (CT) colonography is a noninvasive, rapidly evolving technique that has been shown in some studies to be comparable with conventional colonoscopy for the screening of colorectal cancer. CT colonography is being increasingly applied as a routine screening method for the detection of colorectal cancer in last few years as it is more convenient and less invasive than colonoscopy. In addition, it has an upper hand in diagnosis of small lesions less than 10mm (Choi, et al., 2011).

Patients and methods: This prospective double blind comparative study will be conducted on 23 patients with colorectal symptoms and signs as altered bowel habits, bleeding per rectum, abdominal pain, weight loss, unexplained fatigue and loss of appetite. An informed written consent was obtained from all patients and approval of the faculty research ethics committee was obtained.

Results: Total of 108 colonic lesions were analyzed in 23 patient; Seven colonic masses were diagnosed in 6 patients, 41 polyps in 8 patients and 60 diverticulae in 5 patients.

Six patients had incomplete colonoscopy. Of them, 2 patients had a large polypoidal mass that prevents further colonoscopic introduction. Using CT colonography we were able to evaluate those polypoidal masses. Moreover, we could complete the examination and evaluation of the proximal colon and one of them had a polypoidal sigmoid colon mass and showed another proximal annular mass.

Four patients presented with colonic obstruction and good preparation to the proximal parts of the colon failed, So completing the colonoscopy was difficult. After undergoing CT colonography, 2 patients were normal and 2 patients had annular masses causing proximal obstruction and marked distension.

Conclusion CT Colonography (Virtual Colonoscopy) is a reliable tool and more sensitive for detecting colonic mass lesions larger than 5 mm, polyps larger than 5 mm, strictures and diverticulosis. CTC is of value in evaluating the colonic segment lying proximal to colonic cancers including those with occlusive growths or strictures. Contrast-enhanced CTC is also useful in identifying extra-colonic findings. Virtual Colonoscopy is a good screening tools for malignant or premalignant lesions in patients presented with colorectal symptoms.

INTRODUCTION

Since the introduction of computed tomographic colonography (CTC) or 'virtual colonoscopy' in 1994, there has been marked advance in the development and clinical application of this technique; one advance is the application of multislice CT (MSCT)

technology. MSCT makes high spatial resolution applicable at shorter acquisition times, increasing the sensitivity of the scan to smaller lesions (Ji, et al., 2003).

Colorectal cancer is the third most common cancer and the second leading

cause of cancer-related death in Western countries. As with other malignancies, screening and early detection is fundamental for successful management of colorectal cancer. CT colonography is being increasingly applied as a routine screening method for the detection of colorectal cancer in last few years as it is more convenient and less invasive than colonoscopy (Choi, et al., 2011).

CT colonography provides planar two-dimensional (2D) and virtual 3D endoscopic images of the colon. Although radiologists are traditionally most experienced in 2D CT of the abdomen, the planar 2D approach to

RESULTS

Twenty three patients were recruited for the study, "13 male and 10 female". Their age range from 17 and 75 years old and mean age was 47 ± SD. Sixteen of them were above 50 years old and 7 were below 50 years old. Nine patients were having anaemia and 8 presented by bleeding per rectum. Three patients refused to undergo colonoscopy because of pain as they had piles and was totally free by CT colonography.

the gas-distended colon presents new challenges to "film" readers. The complex intraluminal anatomy of bowel loops, haustral folds, and residual fluid and stool, as well as the degree of distention, may complicate planar evaluation. On the other hand, 3D virtual endoscopy of the large bowel provides an "intraluminal" perspective on CT data that may be unfamiliar to some radiologists. (Mang, et al., 2007).

AIM OF THE WORK:To study role of CT colonography in diagnosis of colorectal diseases in patient with colonic symptoms and signs, compared to colonoscopy.

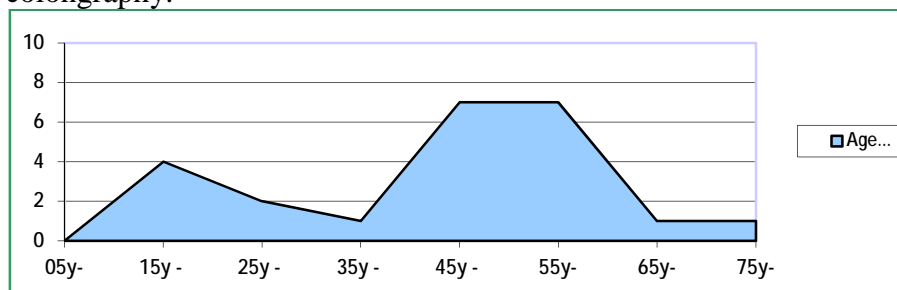


Chart 1. Age distribution of patients under the study.

Our comparative study, the overall sensitivity in detecting colonic diseased patients is 90.9% using CT colonography compared with sensitivity of 72.7% using colonoscopy, and the specificity is 83.3% using CT colonography compared with specificity of 83.3% using colonoscopy.

CTC	Diseased	Non-Diseased
+ve.	10	1
-ve.	1	5

Table 1. Results of the screening test of CTC.

Conventional colonoscopy	Diseased	Non-Diseased
+ve.	8	1
-ve.	3	5

Table 1. Results of the screening test of CC.

Positive predictive value is 90.9% using CT colonography compared with 88.8% using colonoscopy and negative predictive value is 83.3% using CT colonography compared with 62.5% using colonoscopy. All those patients are subjected to surgery and proved that.

In this study the colon was divided into six segments: rectum, sigmoid colon, descending colon, transverse colon (including the splenic and hepatic flexures), ascending colon and caecum, with highest prevalence of polyps at the rectum, sigmoid and descending colon “25%” for each. The smallest polyp detected was 3mm in size and the largest one was 13mm.

Polyps at:	Number of patients	Number of polyps
Rectum.	4	7
Sigmoid colon.	4	8
Descending colon.	4	10
Transverse colon.	1	5
Ascending colon.	2	8
Cecum.	1	3
Total:	In 8 patients	41 polyps

Table 2. Distribution of polyps at different colonic segments.

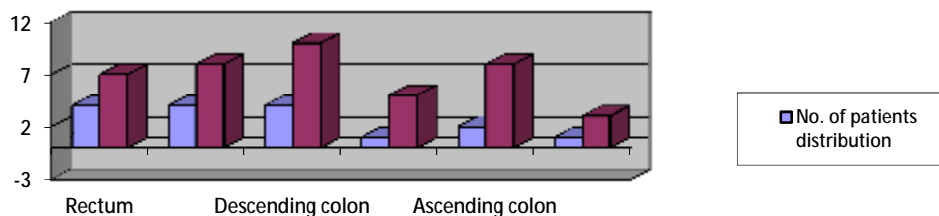


Chart 2.

Distribution of polyps at different colonic segments.

	CC	CTC
Masses	5 in 5 patients	7 in 6 patients
Polyps	6 in one patient	41 in 8 patients
Diverticulae	2 in one patient	60 in 5 patients
Smallest polyp	12mm	3mm

Table 3. Results of Conventional colonoscopy and CT colonography.

We detected 7 colonic masses in 6 patients with the 100% sensitivity and with highest prevalence of masses was at the sigmoid colon and descending colon “28.6%” for each.

Masses at:	Number of masses
Rectum.	1
Sigmoid colon.	2
Descending colon.	2
Transverse colon.	1
Ascending colon.	1
Cecum.	0
Total:	7 masses.

Table 4. Distribution of masses at different colonic segments.

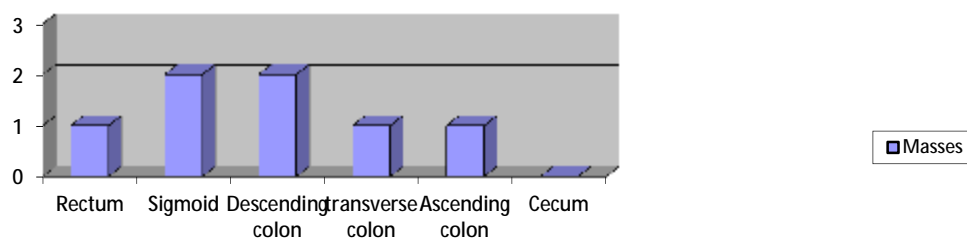
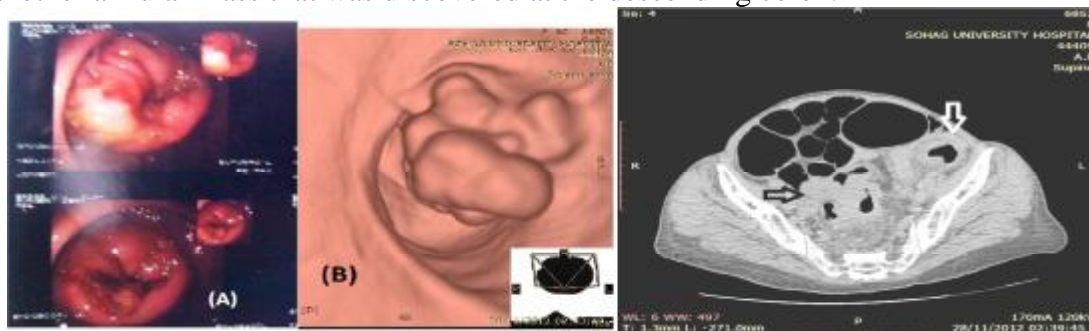


Chart 3. Distribution of masses at different colonic segments.

Six patients had incomplete colonoscopy. Of them, 2 patients had a large polypoidal mass that prevents further colonoscopic introduction. Using CT colonography we were able to evaluate those polypoidal masses; detect their upper extension and measure their size. Moreover we could complete the examination of the proximal colon and one of those two patients with polypoidal sigmoid colon mass showed another annular mass that was discovered at the descending colon.



(c)

Fig. 1. Incomplete colonoscopy because of a large polypoidal cancer of the sigmoid colon(A). Surface-rendered global CT image shows the large polypoidal mass within the sigmoid colon (B) & (Black arrow in C) and a second stenosis in the descending colon (White arrow) seen as circular wall thickening. (Patient was subjected to colonic resection and histopathology revealed another adenocarcinoma in the descending colon that was not diagnosed by colonoscopy.

Four patients presented with colonic obstruction and good preparation to the proximal parts of the colon failed, So completing the colonoscopy was difficult. After undergoing CT colonography, 2 patients were normal and 2 patients had annular masses causing proximal obstruction with marked distension of the proximal colon.

Patients with obstruction:	Level of obstruction:	Results of CTC	Proximal to obstruction
Patient 1	Up to descending colon	Normal study.	Normal.
Patient 2	Up to transverse colon	Normal study.	Normal.
Patient 3	Descending colon	Annular mass at transverse colon measuring 3x1.5x1cm & causing proximal obstruction.	Marked distension by fecal matter with multiple cecal calcifications.
Patient 4	Transverse colon	Cauliflower mass at ascending colon measuring 3x3.5x2cm & causing proximal obstruction.	Marked distension by fecal matter.

Table 5. Patients with colonic obstruction; CTC results: Level of obstruction and effect.

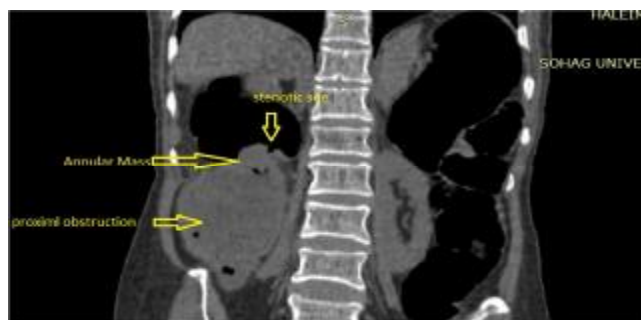


Fig. 2. Incomplete colonoscopy because of ascending colon cauliflower mass with shouldering causing distension of the proximal part of the ascending colon by fecal matter. As we resort to inflate the colon using air in CT colonography, so detection of diverticulae was easier by CT colonography than colonoscopy. We could detect up to 60 diverticulae in 5 patients with sensitivity of about 99%. The largest diverticula detected measured 15mm and the smallest one measured 2.5mm.

(A)

(B)

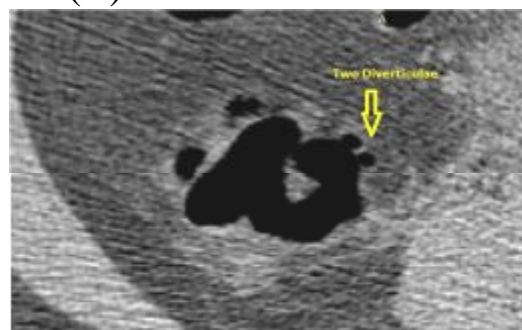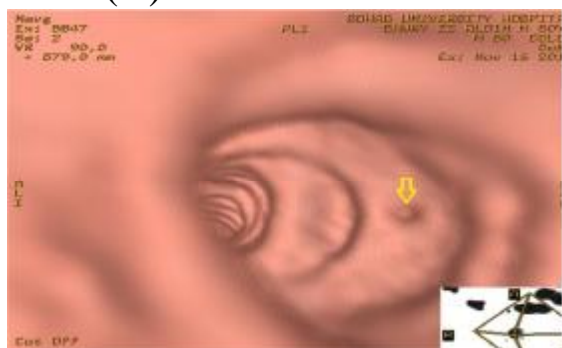
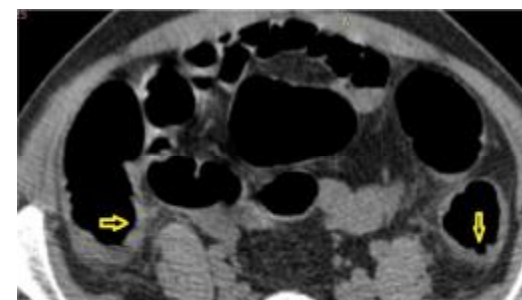

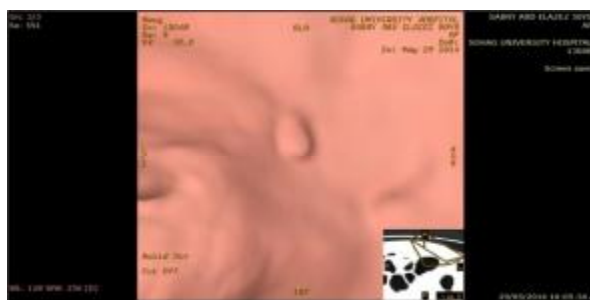
Fig. 3. Defect of small diverticula is seen at 3D reconstruction (A) and two small diverticulae are seen at axial scan (B).

Two patients with ulcers and with ulcerative colitis detected by colonoscopy, one of them was missed using colonography. So ulcers are difficult to be detected by colonography as they are a small depressions in the mucosal walls. More easier a mucosal wall thickening with well defined depressions may be detected in advance cases of ulcerative colitis as seen in the other case.



(A)

(B)

Fig. 4. 3D virtual reconstruction revealed ulcer defect (A). Axial scans showed thickened edematous wall of ascending and descending colon with small well defined depression in the thickened mucosa(B).

Incidental extra-colonic findings are detected in two patients; one patient with large colonic mass we found a hepatic focal lesion that biopsy proved that is metastatic adenocarcinoma. Another patient with descending colon mass, the 2D axial evaluation

revealed that the mass extends to the serosa with surrounding fat stranding and regional LNs enlargement, which indicates advanced stage of the disease.

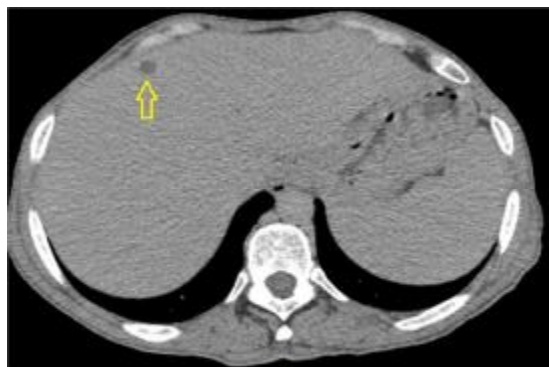


Fig. 5. Patient with colonic adenocarcinoma. There is a small hypodense hepatic focal lesion that proved by biopsy and histopathology that it is a metastatic hepatic lesion.

DISCUSSION

Comparison between virtual and conventional colonoscopy as regards their results and sensitivity for colonic lesions detection has been the goal for several studies in order to assess the accuracy of virtual colonoscopy.

In our study, the overall sensitivity of Virtual colonography in polyp detection was 85.7% with Sensitivity 100% and Specificity 84.3% for the detection of large polyps 10 mm or more; Sensitivity and specificity 100% for polyps 5-10 mm and Sensitivity 42.9% and Specificity 93.4% for polyps smaller than 5 mm which matched the results of **Gluecker et al., (2009)** who reported the overall sensitivity of virtual colonoscopy in polyp detection was 85.3%, with sensitivity for small polyp detection 65% and medium sized polyp detection 97% and large polyp detection 100% and **(Kalra et al., 2009)**, who reported sensitivity 65 % and specificity 92% in small polyps detection, Sensitivity 97% and specificity 93% in medium sized polyp detection and sensitivity 100% and specificity 88% in large polyp detection.

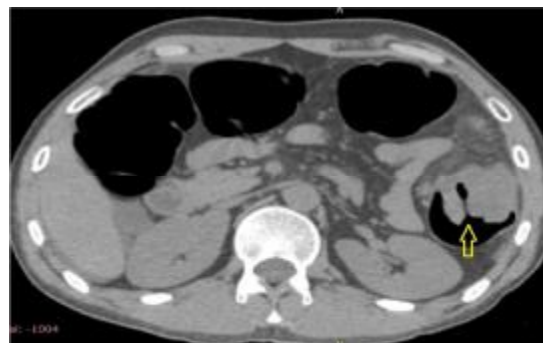

Fig. 6. Patient with descending colon mass showing peri-colic fat stranding.

Most authors reported overall sensitivity of virtual colonoscopy in polyps detection “ 84%-88.4%” and sensitivity of “75-100%” for the detection of large polyps 10 mm or more , “66-100%” for polyps 5-10 mm and “45-70%” for polyps smaller than 5 mm which agreed with our results. **(Hara et al., 1996 , Fenlon et al., 1999 , Morrin et al., 1999 and yee et al., 2001 & 2003).**

Ongoing research support the notion that CT colonography is a sensitive and specific method for detecting polyps. Although the results are promising, concerns exist as to whether CT colonography will be equally effective when placed into general use **(Summer et al., 2005).**

In our study, The false positive results in virtual colonography detection in large polyps was due to misinterpretation of the ileo-caecal valve as a large caecal polyp which was one of the disadvantages of virtual colonoscopy examination as in our study there were 3 false positive results in virtual Colonoscopy as it diagnosed the ileo-caecal valve as a large polyp.

Virtual dissection images may bypass and not detect lesions commonly small in size such as polyps less than 5 mm. Regarding our study, therefore, the main missed lesions in virtual Colonoscopy were “2” polyps smaller than 5 mm (from total 4 small polyps detected by conventional colonoscopy with sensitivity 42.9% as they were also 2 false positive small polyps) small sessile or flat polyps as where they were mistaken as normal mucosal colonic folds, also regarding for “3” patients with ulcerative colitis just was presented by hyperemic mucosa and flat ulcers, but no pseudopolyps. As they were flat lesions, all were not detected by the virtual colonoscopy.

Our results match the results of **Park et al.**, who reported that flat lesions, ulcers, vascular lesions, non-complicated flat inflammatory lesions and small polyps are the main causes for missed lesions at CT colonography. When all flat, sessile or pedunculated lesions are included, sensitivity was 75% for lesions 10 mm or larger, and 79% for those 6 mm or larger. when only sessile and pedunculated lesions were included, corresponding sensitivities were 100% and 98% respectively which match our results. All missed lesions larger than 10 mm were flat. Sessile or pedunculated polyps 5 mm or smaller were more likely to be missed more than those 6 mm or larger. (**Park et al., 2009**).

On the other hand, our study did not agreed with **Bond.**, who reported a 95% sensitivity of virtual colonoscopy in small polyp detection because the multislice CT he used had more advanced technology and higher speed with very thin slice thickness. (**Bond., 2009**).

One early perceived weakness of VC (Virtual colonography) was its low sensitivity in detecting flat lesions. **Pickhardt et al.**, demonstrated that VC detected 83% of flat adenomas and

80% of all flat lesions 6 mm or greater. Before they could be visualized, flat lesions were 2 mm or greater in height and 7 mm or greater in diameter. It seems therefore that below 6–7 mm these flat lesions are currently difficult to be seen on CT, but it is worth noting that advanced histology in such lesions is very rare (0 out of 148 such lesions detected in **Pickhardt’s** study on CC were advanced). (**Pickhardt et al., 2008**). The results of the previous study meet the results of our study in confirming the pitfalls of VC in detecting flat lesions but these results did not matches our results regarding medium sized lesions as the sensitivity of VC in our study in detection of lesions greater than 5 mm was 100%.

In our study, there were four (4) patients with colonic polypoidal masses in whom conventional colonoscopy failed to pass and to complete the study, but Virtual colonoscopy was able to detect them with sensitivity 100% and was able to complete the study in those patients. One of them had another annular mass was discovered at the descending colon, which agreed with **Iannaccone et al., 2008**, who has reported a sensitivity of 100% for virtual colonoscopy in the detection of both strictures and colonic masses lesions and discovered lesions proximal to the occlusive growth (mass or stricture) in 45 out of 100 patients, other authors reported similar results (**Fenlon et al., 1999; Zalis et al., 2001 ; Yee et al., 2001 and 2003**).

In another study, the role of Virtual colonoscopy after incomplete Conventional colonoscopic examination was evaluated. all subjects had stenotic colonic segments which conventional colonoscopy could not bypass. Among these patients CT Virtual colonoscopy was able to detect 10 lesions (masses and polyps) in the

proximal colonic segments. (Emanuele et al., 2009).

In our study, we applied combined supine and prone technique during the Virtual Colonoscopy in most of the patients, as it improves colonic distension and redistribution of gas, residual fluids and fecal matter residue, which are the most common causes of decreased colonic wall conspicuity, leading to false results. Most authors reported significant improvement in the overall sensitivity for polyp detection by using combined positions as opposed to using either position alone (Yee et al., 2009) and (Talyor et al., 2008), However, other authors refrained from using the combined supine and prone techniques as this increases the radiation dose to the patient and also costs and doubles the examination time (Chen et al., 2009).

Rogalla et al., suggested that axial supine CT images of all patients were reviewed while the patient is still on the table and the decision on additional prone position scans, or not, where inadequate colonic preparation and distension may be present.

Incidental extra-colonic findings on CT Colonography were common in our study. but we could not comment on the sensitivity of virtual colonoscopy in detection as the conventional colonoscopy is an intaluminal procedure that can't detect the extracolonic lesions. Many authors reported multiple side finding in CT colonoscopy in patients with Colonic symptoms, including lymphadenopathy, aneurysmal dilatation of the aorta, vertebral column changes, pancreatic pseudocyst, leiomyoma of the uterus, renal cyst, steato-hepatitis, and hemangiomas of the liver (Rogalla et al., 2007).

However, in a number of studies, CT colonographies, potentially important findings were revealed that led to

additional diagnostic actions or therapeutic interventions. Some of these findings were clinically important, but others led to unnecessary further workup. These factors must be taken into account when evaluating the role of CT Colonography in routine diagnostic workup and in screening. (Johnson et al., 2008) & (Svensson et al., 2002).

In patients with intestinal obstruction in our study where good preparation failed and as a result the lower endoscopy failed. Although CT colonography needs good preparation, we detected four masses causing the obstruction with proximal colonic dilatation. Our previously mentioned results meets the results of (Kalra et al., 2009) & (Iannaccone et al., 2008) who reported a sensitivity of 100% in masses and large polyps detection by the virtual colonography, also our study agreed with Lieberman et al., who reported a 100 % sensitivity of virtual colonoscopy in large polyps and masses detection (Lieberman et al., 2007).

Many studies have repeatedly stressed a role of Virtual Colonoscopy in colorectal cancer (CTC) screening, with excellent sensitivity for polyps (the precursor of colorectal cancer) masses and malignant strictures with safety and acceptability (Mulhall et al., 2005). Also regarding to the studies conducted by (Kalra et al., 2009), (Iannaccone et al., 2008), (Fenlon et al., 1999; Zalis et al., 2001; Yee et al., 2001 and 2003). This high sensitivity in virtual colonoscopy examination in patients with constipation was because patients with constipation have colonic masses or large polyps which were all detected by the virtual colonoscopy (sensitivity of virtual colonoscopy in mass and large polyps detection was 100% for both).

Also CT colonography has advantages over the conventional colonoscopy due to its ability to diagnose extra-colonic spread and detect the mural tumor invasion with high efficacy in Colorectal carcinoma staging with detection of lymph node or liver

CONCLUSION

In Conclusion, multi-detector CT Colonography (Virtual Colonoscopy) is a reliable tool for detecting colonic mass lesions larger than 5 mm, polyps larger than 5 mm, strictures and diverticulosis. CTC is of value in evaluating the colonic segment lying proximal to the main lesions, such as colonic cancers including those with occlusive growths or strictures. Contrast-enhanced CTC is also useful in identifying extra-colonic findings.

Virtual Colonoscopy is a good screening tools for malignant or premalignant lesions in patients presented with constipation or weight loss, and also it help in staging of colorectal carcinoma regarding the

metastasis, but on the other hand, Virtual Colonography has a very unaccepted pitfall in such patients as we can't perform a diagnostic biopsy from the causative lesion which is essential to diagnose the nature of such lesions.

detection of tumor mural growth , lymph node or liver metastasis also in diagnosis of associated extra-colonic lesions as ascities which could not be done by conventional colonoscopy but its use as a good diagnostic tool is limited due to inability for a diagnostic biopsy from such lesions.

Inability to take a diagnostic biopsy from the lesion or therapeutic procedures to stop bleeding as polypectomy, Argon Plasma coagulation in case of angiodysplasia or bleeding ulcers, inability to perform ligation of internal piles have made the Virtual Colonography non-suitable diagnostic procedure in patients with bleeding per-rectum.

REFERENCES

- 1- **Barish MA, Soto JA, Ferrucci JT.** Consensus on current clinical practice of virtual colonoscopy. *AJR Am J Roentgenol* 2005;184:786-92
- 2- **Brown G, Kirkham A, Williams GT, et al:** High-resolution MRI of the anatomy important in total mesorectal excision of the rectum. *AJR* 2004; 182:431-439.
- 3- **Burling D, Taylor SA, Halligan S, et al.** Automated insufflation of carbon dioxide for MDCT colonography: distension and patient experience compared with manual insufflation. *AJR Am J Roentgenol* 2006;186:96-103.
- 4- **Charanjeet Singh.** colon tumours outlines, 2003-2011.
- 5- **Charanjeet Singh.** colon tumours outlines, 2003-2012.
- 6- **Chen JS, Hsieh PS, Chiang JM, et al.** Clinical outcome of signet ring cell carcinoma and mucinous adenocarcinoma of the colon. *Chang Gung Med J* 2010;33:51-7.
- 7- **Dachman AH, Kuniyoshi JK, Boyle CM, et al.** CT colonography with three dimensional problem solving for detection of colonic polyps. *AJR Am J Roentgenol* 1998;171:989-95.
- 8- **Edge SB, Byrd DR, Compton CC, et al.** *AJCC Cancer Staging Handbook*, 7th edition. New York: Springer, 2010:173-206.
- 9- **Fenlon HM, Clarke PD, Ferrucci JT.** Virtual colonoscopy: imaging features with colonoscopic correlation. *AJR Am J Roentgenol* 1998;170:1303-9.
- 10- **Fletcher JG, Johnson CD, Krueger WR, et al.** Contrast-enhanced

- CT colonography in recurrent colorectal carcinoma: feasibility of simultaneous evaluation for metastatic disease, local recurrence, and metachronous neoplasia in colorectal carcinoma. *AJR Am J Roentgenol* 2002;178:283–90.
- 11 - Gluecker TM, Johnson CD, Wilson LA, et al.** Extracolonic findings at CT colonography: evaluation of prevalence and cost in a screening population. *Gastroenterology* 2003;124:911–6.
- 12- Halligan S, Altman DG, Taylor SA, et al.** CT colonography in the detection of colorectal polyps and cancer: systematic review, meta analysis, and proposed minimum data set for study level reporting. *Radiology* 2005;237:893–904.
- 13- Hamilton SR, Aaltonen LA:** World Health Organization classification of tumours. Pathology and genetics, tumours of the digestive system, IARC Press, 2000.
- 14-Hamilton SR, Bosman FT, Boffetta P, et al.** Carcinoma of the colon and rectum. In: WHO Classification of Tumours of the Digestive System. Bosman FT, Carneiro F, Hruban RH, Theise ND, eds. Lyon: IARC Press, 2010:134-46.
- 15-Iannaccone R, Laghi A, Catalano C, et al.** Computed tomographic colonography without cathartic preparation for the detection of colorectal polyps. *Gastroenterology* 2004;127:1300–11.
- 16-Isaacson PG:** Lymphoproliferative disorders of the gastrointestinal tract In Pathology of the gastrointestinal tract, second edition, Ming SC, Goldman H.
- 17-J.G. Fletcher, Fargol Booya, C. Daniel Johnson, David Ahlquist.** *Curr Opin Gastroenterol.* 2005;21(1):90-98.
- 18-Juchems MS, Fleiter TR, Pauls S, Schmidt SA, Brambs HJ, Aschoff AJ.** CT colonography: comparison of a colon dissection display versus 3D endoluminal view for the detection of polyps. *Eur Radiol* 2006;16:68–72.
- 19-Laghi A.** Virtual colonoscopy: clinical application. *Eur Radiol* 2005;15(Suppl 4):D138–41.
- 20-Laks S, Macari M, Bini EJ.** Positional change in colon polyps at CT colonography. *Radiology* 2004;231:761–6.
- 21- Lefere P, Gryspeerdt S, Baekelandt M, Dewyspelaere J, van Holsbeeck B.** Diverticular disease in CT colonography. *Eur Radiol* 2003;13(Suppl 4):L62–74.
- 22-Leopoldo S, Lorena B, Cinzia A, et al.** Two subtypes of mucinous adenocarcinoma of the colorectum: clinicopathological and genetic features. *Ann Surg Oncol* 2008;15:1429–39.
- 23-Macari M, Bini EJ, Jacobs SL, Lange N, Lui YW.** Filling defects at CT colonography: pseudo- and diminutive lesions (the good), polyps (the bad), flat lesions, masses, and carcinomas (the ugly). *Radiographics* 2003;23:1073–91.
- 24-Macari M, Bini EJ, Xue X, et al.** Colorectal neoplasms: prospective comparison of thin-section low-dose multi-detector row CT colonography and conventional colonoscopy for detection. *Radiology* 2002;224:383–92.
- 25-Macari M, Bini EJ.** CT colonography: where have we been and where are we going? *Radiology* 2005;237:819–33.
- 26-Macari M, Milano A, Lavelle M, Berman P, Megibow AJ.** Comparison of time-efficient CT colonography with two- and three-dimensional colonic evaluation for detecting colorectal polyps. *AJR Am J Roentgenol* 2000;174:1543–9.
- 27-Makino T, Tsujinaka T, Mishima H, et al.** Primary signet-ring cell carcinoma of the colon and rectum: report of eight cases and review of 154 Japanese cases. *Hepatogastroenterology* 2006;53:84 5-9.
- 28-Mang T, Maier A, Plank C, Mueller-Mang C, Herold C, Schima W.** Pitfalls in Multi-Detector Row CT Colonography: A

- Systematic Approach. *RadioGraphics* 2007; 27:431–454.
- 29- **Ming SC, Goldman H:** Pathology of the gastrointestinal tract, second edition, Philadelphia, 1998, Williams and Wilkins.
- 30-**Morrin MM, Farrell RJ, Kruskal JB, Reynolds K, McGee JB, Raptopoulos V.** Utility of intravenously administered contrast material at CT colonography. *Radiology* 2000;217:765–71.
- 31- **Neri E, Giusti P, Battolla L, et al.** Colorectal cancer: role of CT colonography in preoperative evaluation after incomplete colonoscopy. *Radiology*, 2002;223:615–9.
- 32-**Owen DA, Kelly JK:** Atlas of gastrointestinal pathology, Philadelphia, 1994, Saunders, p170
- 33- **PJ, Choi JR, Hwang I, et al.** Computed tomographic virtual colonoscopy to screen for colorectal neoplasia in asymptomatic adults. *N Engl J Med* 2003;349:2191–200.
- 34-**Pickhardt PJ.** Translucency rendering in 3D endoluminal CTcolonography: a useful tool for increasing polyp specificity and decreasing interpretation time. *AJR Am J Roentgenol* 2004;183:429–36
- 35- **BJ, Fujii T, Cairns A, et al.** Flat and depressed colonic neoplasms: a prospective study of 1000 colonoscopies in the UK. *Lancet* 2000;355:1211–4.
- 36-**Rockey DC, Paulson E, Niedzwiecki D, et al.** Analysis of air contrast barium enema, computed tomographic colonography, and colonoscopy: prospective comparison. *Lancet* 2005;365:305–11.
- 37-**Rogalla P, Lembcke A, Ruckert JC, et al.** Spasmolysis at CT colonography: butyl scopolamine versus glucagon. *Radiology* 2005;236:184–8.
- 38-**Royster AP, Fenlon HM, Clarke PD, Nunes DP, Ferrucci JT.** CT colonoscopy of colorectal neoplasms: two-dimensional and three dimensional virtual-reality techniques with colonoscopic correlation. *AJR Am J Roentgenol* 1997;169:1237–42.
- 39- **Sosna J, Blachar A, Amitai M, et al.** Colonic perforation at CT colonography: assessment of risk in a multicenter large cohort. *Radiology* 2006;239:457–63.
- 40-**Stoker J, Bartram CI, Halligan S:** Imaging of the posterior pelvic floor. *Eur Radiol* 2002; 12:779-788.
- 41-**Summers RM, Yao J, Pickhardt PJ, et al.** Computed tomographic virtual colonoscopy computer-aided polyp detection in a screening population. *Gastroenterology* 2005;129:1832–44.
- 42-**Svensson MH, Svensson E, Lason A, Hellstrom M.** Patient acceptance of CT colonography and conventional colonoscopy: prospective comparative study in patients with or suspected of having colorectal disease. *Radiology* 2002;222:337–45.
- 43-**Taylor SA, Halligan S, Bartram CI.** CT colonography: methods, pathology and pitfalls. *Clin Radiol* 2003;58:179–90.
- 44- **Taylor SA, Halligan S, Goh V, Morley S, Atkin W, Bartram CI.** Optimizing bowel preparation for multidetector row CT colonography: effect of Citramag and Picolax. *Clin Radiol* 2003;58:723–32.
- 45-**Taylor SA, Halligan S, Saunders BP, et al.** Use of multidetector-row CT colonography for detection of colorectal neoplasia in patients referred via the Department of Health “2-week-wait” initiative. *Clin Radiol* 2003;58:855–61.
- 46- **Thirunavukarasu P, Sathaiah M, Singla S, et al.** Medullary carcinoma of the large intestine: a population based analysis. *Int J Oncol* 2010;37:901 7.
- 47- **Thomas Mang, Anno Graser, Wolfgang Schima, Andrea Maier:** CT colonography: Techniques, indications, findings. *European Journal of Radiology* 61 (2007) 388–399.
- 48- **van Gelder RE, Birnie E, Florie J, et al.** CT colonography and colonoscopy: assessment of patient preference in a 5-week follow-up study. *Radiology* 2004;233:328–37.
- 49- **Verhulst J, Ferdinande L, Demetter P, et al.** Mucinous subtype as prognostic

factor in colorectal cancer: a systematic review and meta analysis. *J Clin Pathol* 2012;65:381-8.

- 50- Vos FM, van Gelder RE, Serlie IW, et al.** Three-dimensional display modes for CT colonography: conventional 3D virtual colonoscopy versus unfolded cube projection. *Radiology* 2003;228:878–85.
- 51- Winawer SJ, Stewart ET, Zauber AG, et al.** A comparison of colonoscopy and double-contrast barium enema for surveillance after polypectomy. National Polyp Study Work Group. *N Engl J Med* 2000;342:1766–72.
- 52- Yee J, Kumar NN, Hung RK, Akerkar GA, Kumar PR, Wall SD.** Comparison of supine and prone scanning separately and in combination at CT colonography. *Radiology* 2003;226:653–61.
- 53- Yoshida H, Dachman AH.** CAD techniques, challenges, and controversies in computed tomographic colonography. *Abdom Imaging* 2005;30:26–41.
- 54- Zalis ME, Barish MA, Choi JR, et al.** CT colonography reporting and data system: a consensus proposal. *Radiology* 2005;236:3–9.