

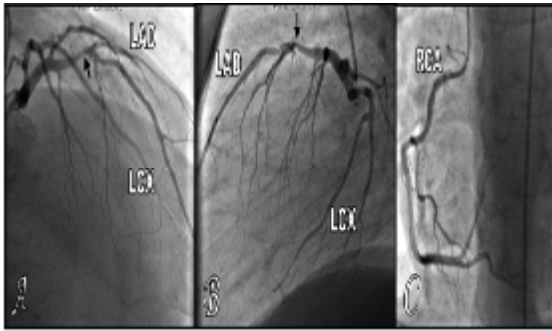Figure 2. SPECT findings in case 1. **A-B:** Short axis. **C-D:** Vertical and horizontal long axis., first row is stress images and second row is rest images. Arrows refer to persistent fixed defect (decreased tracer uptake) in stress and rest images denoting large scar along the apex, septum, anterior and infero-apical segments of the left ventricular wall.

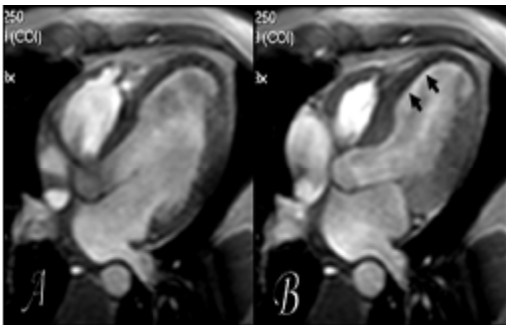
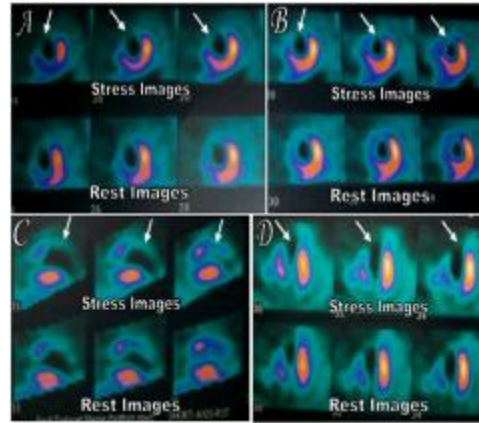


Figure 3. MR findings in case 1. ECG gated TFE cine sequence in four chamber plane of the heart in diastole (A) and in systole (B). Showing moderate dilatation of the left ventricle. Arrows refer to the thinning of the anteroseptal and septal segments of the left ventricular wall at the mid-cavitary and apical levels.

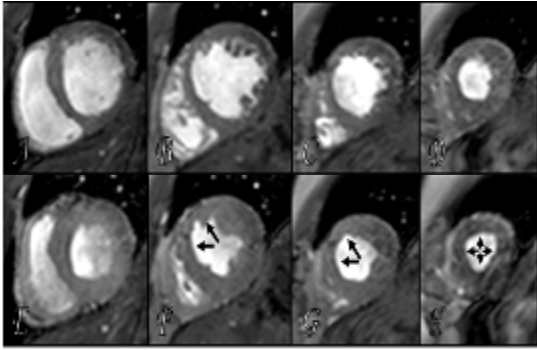


Figure 4. MR findings in case 1. **A-E:** ECG gated TFE cine sequence in short axis plane of the heart in diastole. **F-H:** ECG gated TFE cine sequence in short axis plane of the heart in systole. Arrows refer to the thinning of the anteroseptal and septal segments of the left ventricular wall at the mid-cavitary and apical levels.

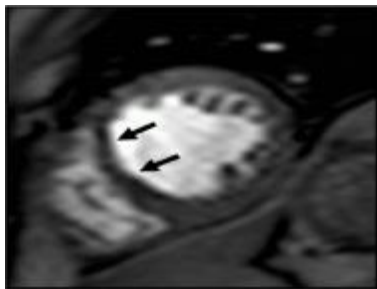
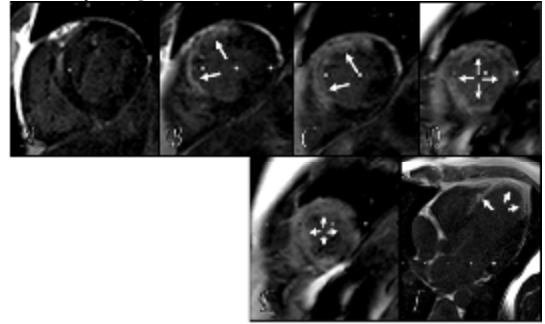


Figure 5. MRI findings in case 1. ECG gated dynamic 2D EPI sequence in short axis plane at the mid-cavitary level. Arrows refer to perfusion defect at the anteroseptal wall at the mid cavitory level.

§ In the 3D IR sequence, there is transmural (75-100 %) enhancing scar at the left ventricular wall involving anterior, anteroseptal and septal segments at the mid-cavitary and apical levels and extends to involve the cardiac apex circumferentially (*Figure 6*).



§

