

Figure (1): .mean AP and T diameters of jugular foramen in 100 adult skulls.

C) Septation: on the right side: 22% had complete septum, 71% had partial septation and 7% no septum was present. On the left side: 20% complete septation, 77% had partial septation and 3% no septation (Figure 2, 3 and 4b, c, d).

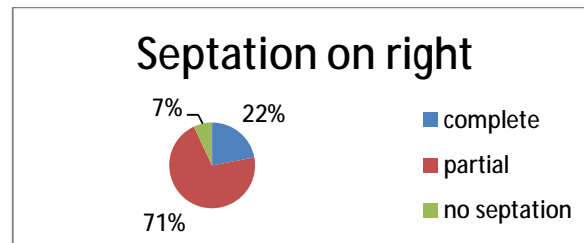


Figure (2): Septation of right jugular foramen in 100 adult skull.

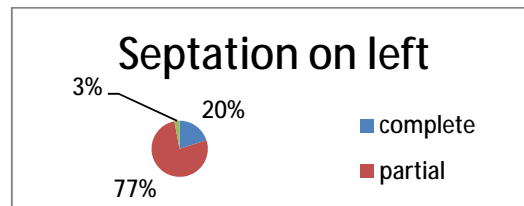


Figure (3): Septation of left jugular foramen in 100 adult skull.



Figure (4): (A) dome (B) and (C) complete separation of jugular foramen. (D) partial separation of jugular foramen.