

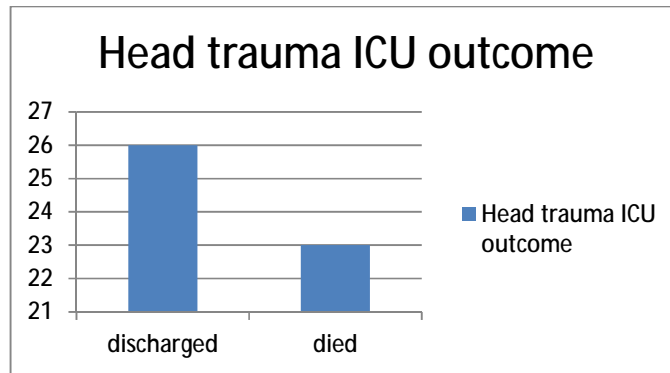Fig ( 1 ) head trauma ICU outcome

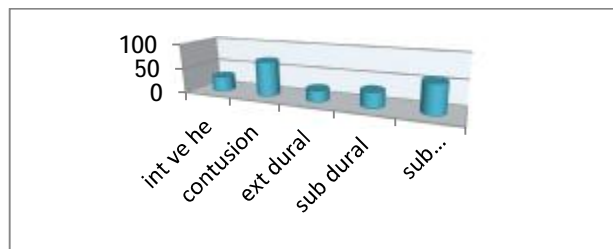


Fig (2) Types of brain injury

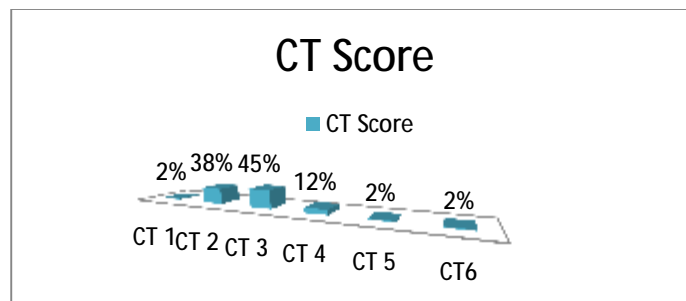


Fig (3) Marshall CT score

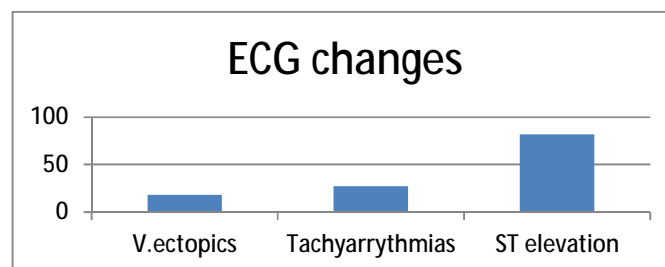


Fig ( 4 ) Abnormalities of ECG frequencies

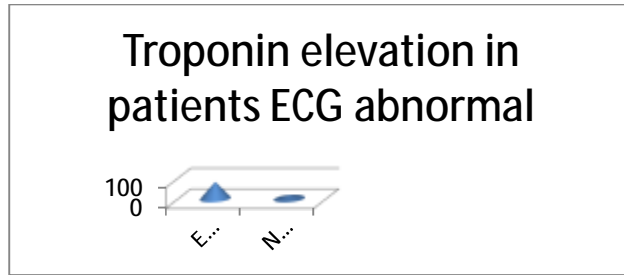


Fig ( 5 ) Troponin elevation in patients with ECG abnormalities

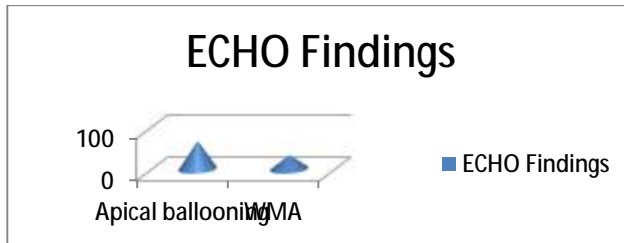


Fig (6) Echocardiography findings in elevated Troponin Pts.