

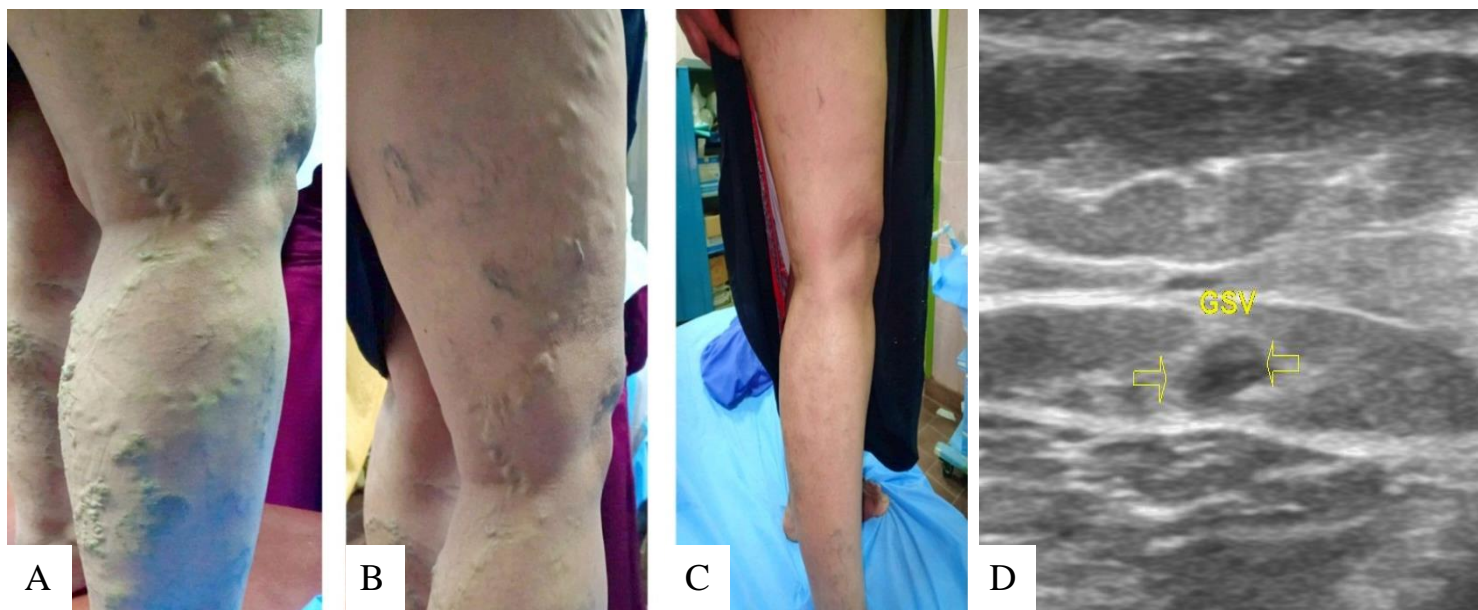Figure 33 Case no. 2: (A) (B) marked visible varicosities. (C) After three sessions of UGFS, Showing significant improvement. (D) Ultrasound study, the GSV thrombosed and non-compressible with marked reduction in diameter.

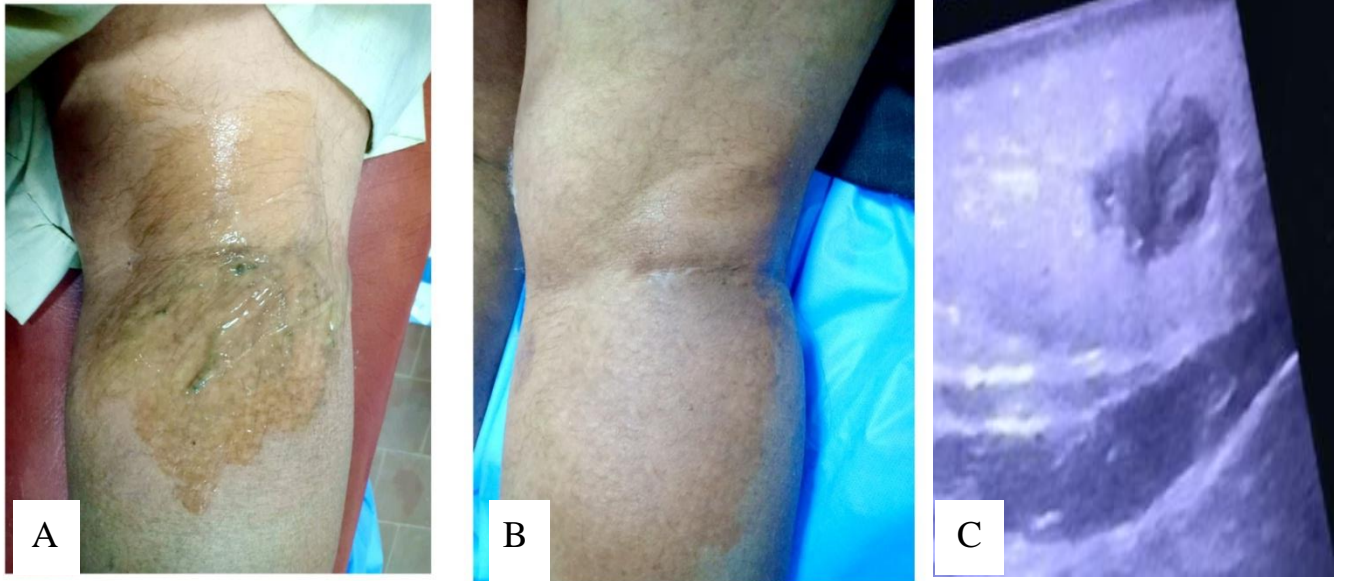


Figure 35 Case no. 4: (A) *subcutaneous varicosities at posterior aspect of upper leg.* (B) *After one session of UGFS, total disappearance of varicosities.* (C) *Ultrasound examination, the treated vein totally thrombosed with fibrosis changes.*

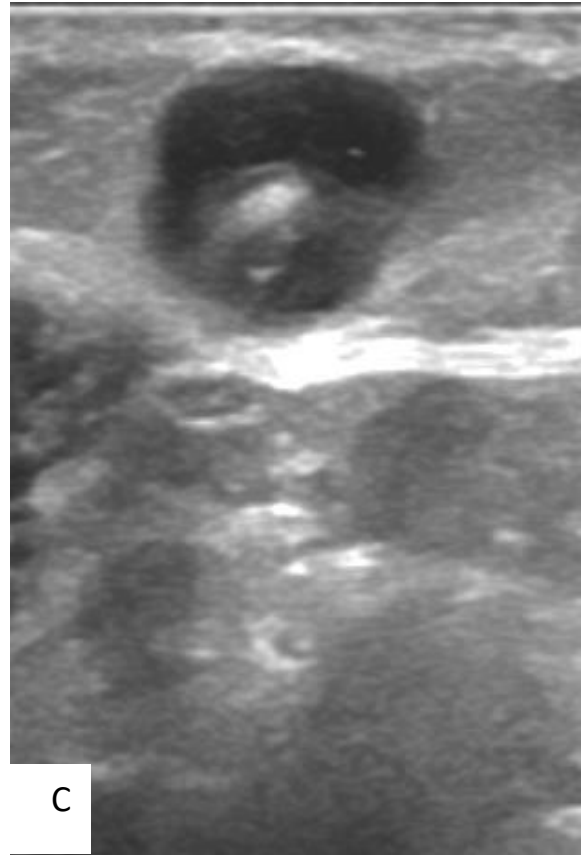
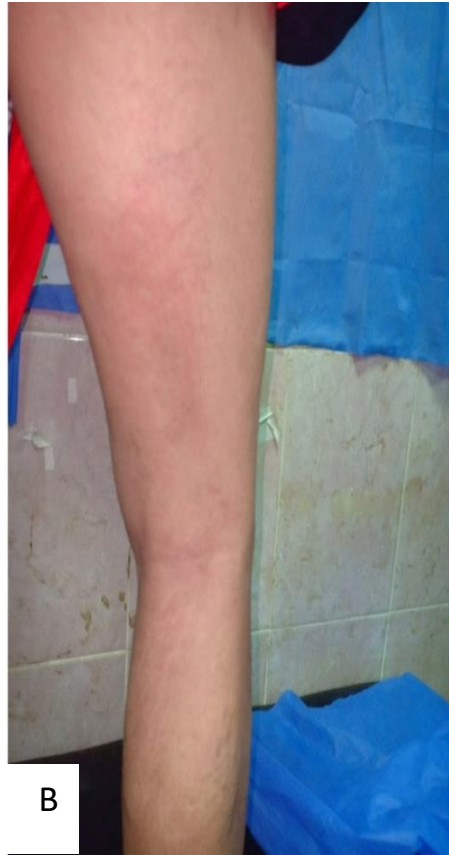
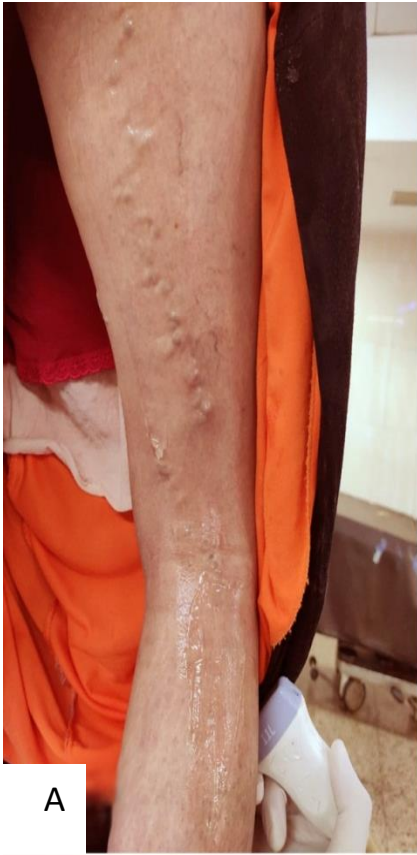
Figure 37 Case no. 6: (A) Large sized subcutaneous varicosities seen at posterior aspect of thigh. (B) No visible varicose vein after UGFS. (C) Ultrasound showing complete thrombosis of treated vein.

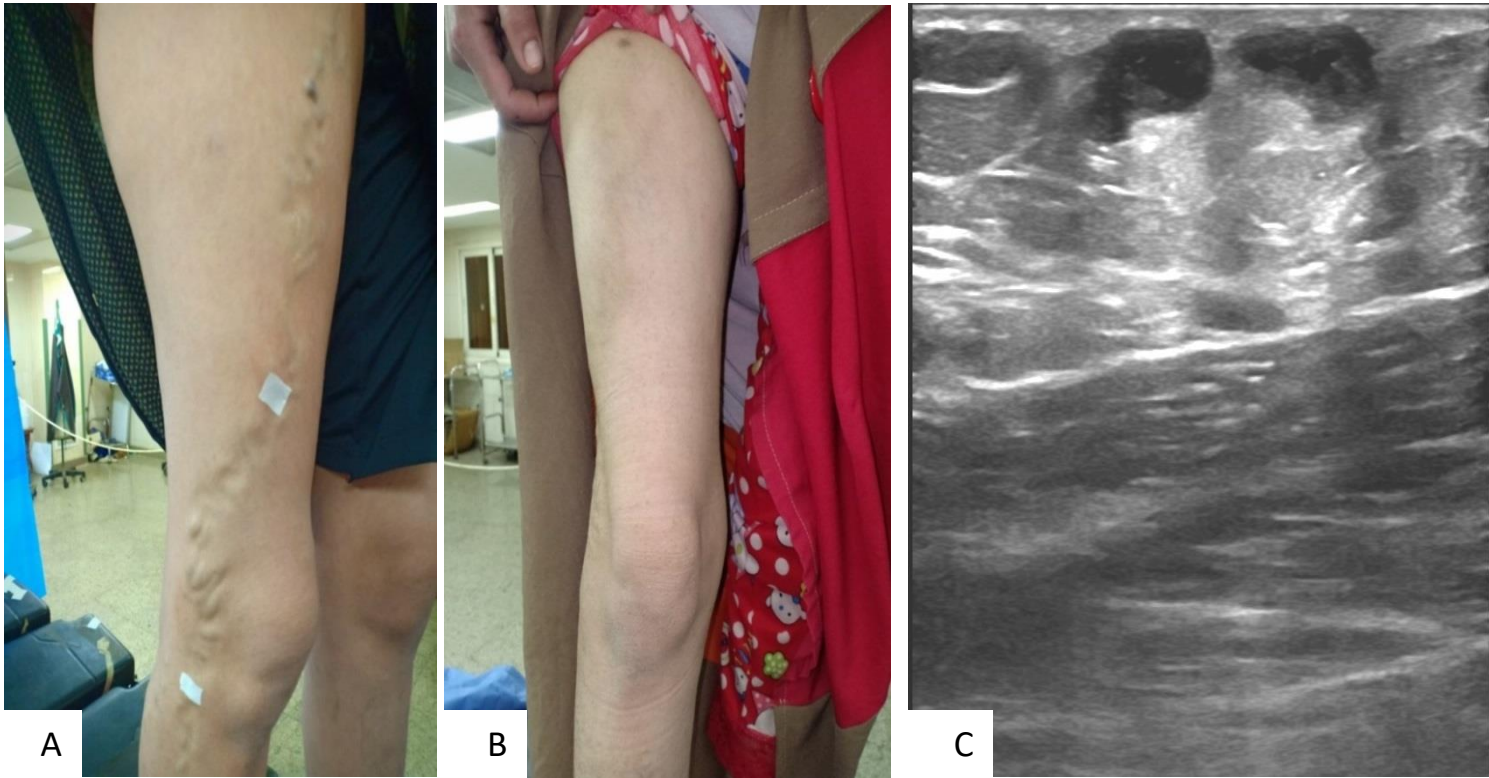


Figure 38 Case no. 7: (A) subcutaneous varicosities related to refluxing large anterior accessory saphenous vein with abnormal course. (B) Disappearance of varicosities after UGFS. (C) Ultrasound image showing complete thrombosis of treated vein with fibrosis changes.