

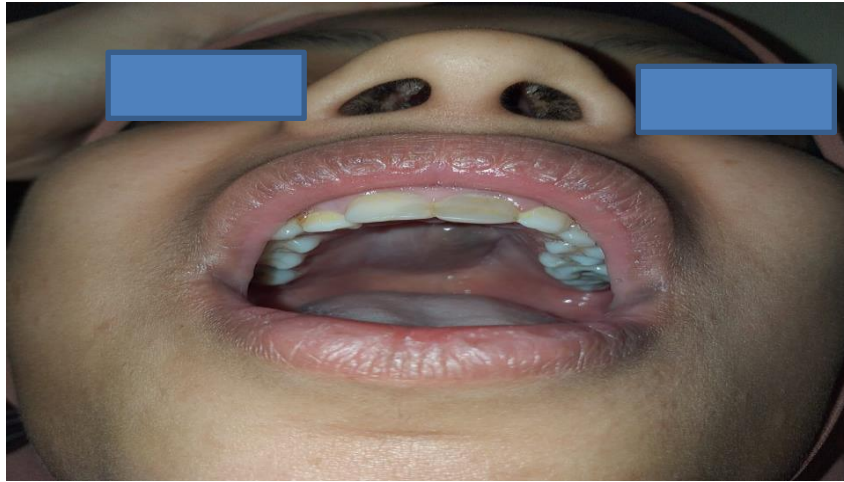Fig. (1) The mass seen from the mouth

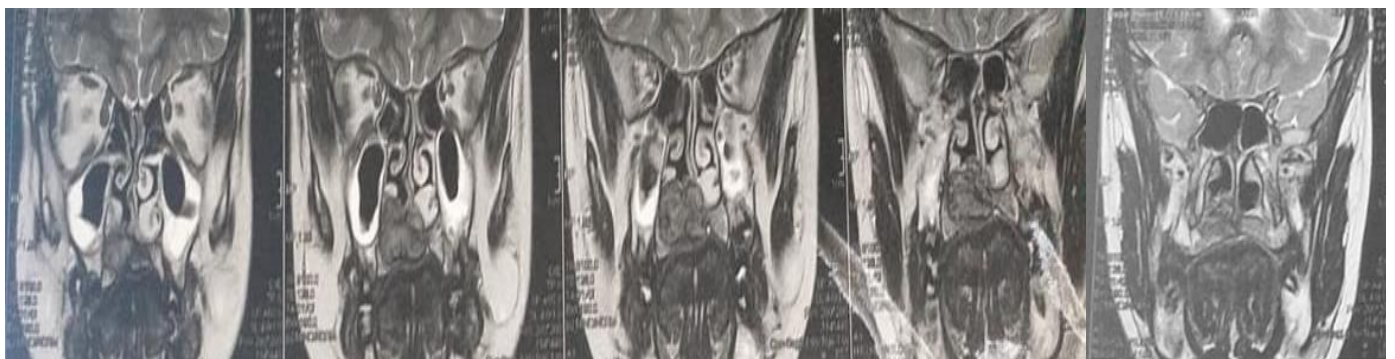
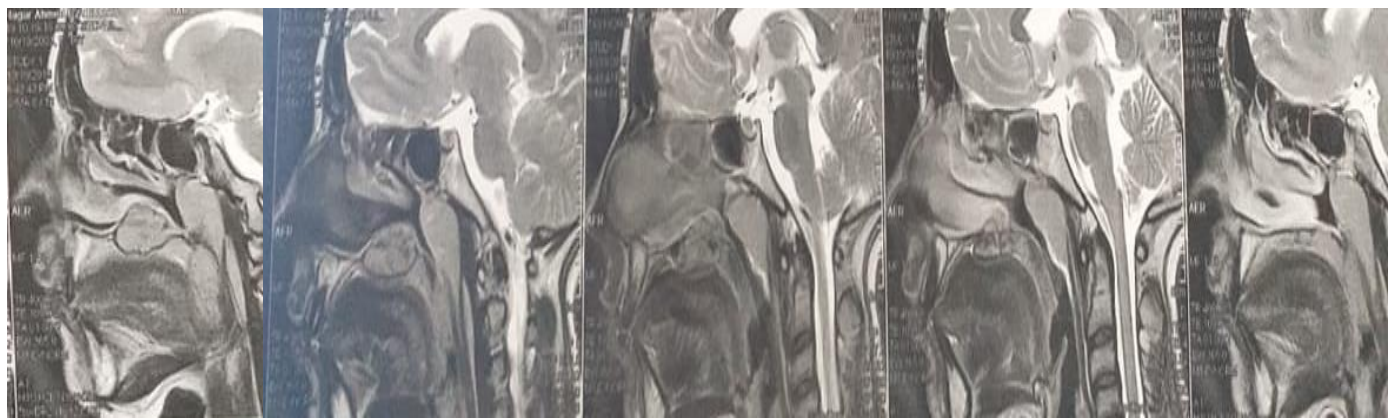
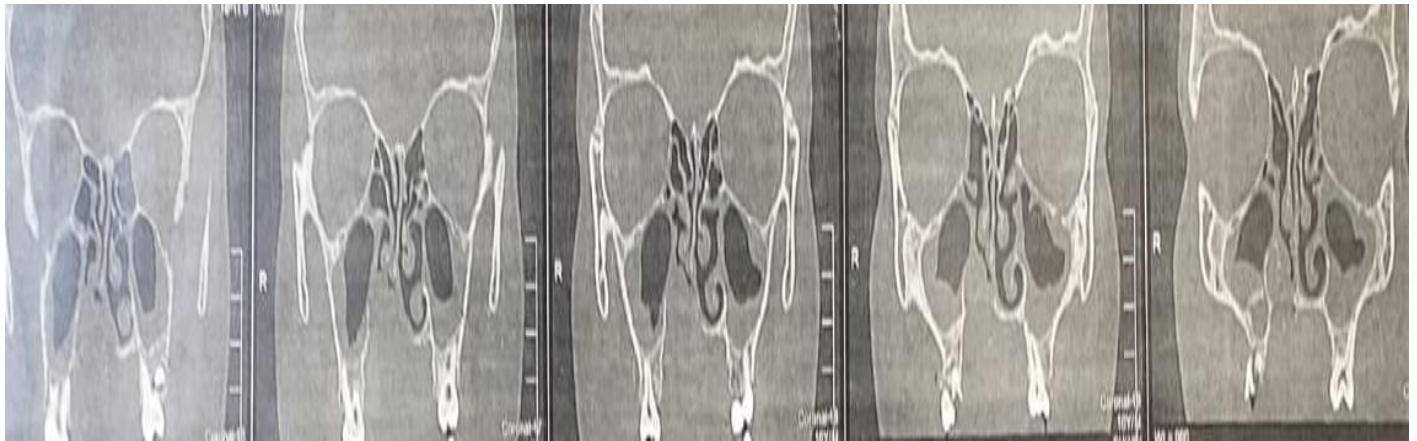
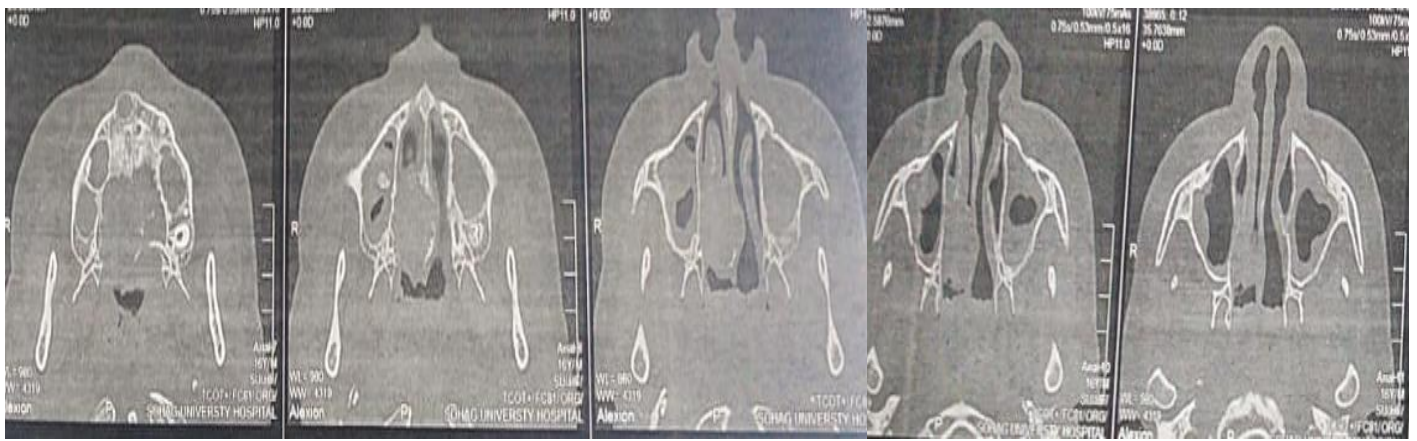

Fig. (2) pre-operative CT& MRI images axial ,coronal & sagittal cuts



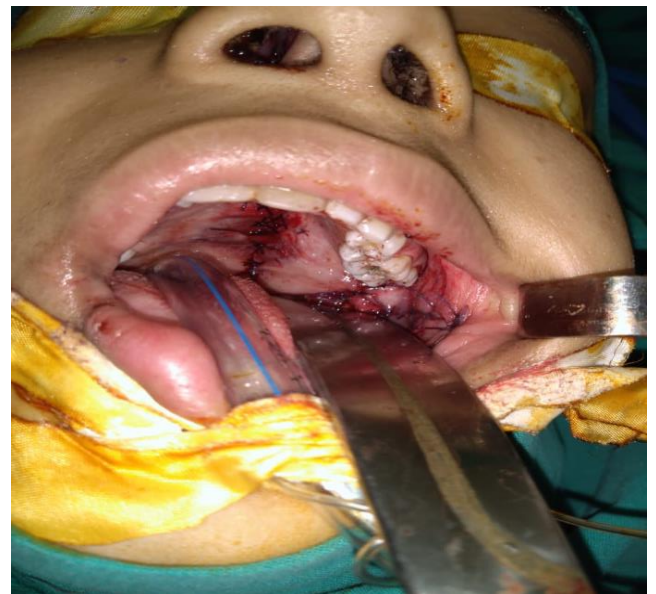
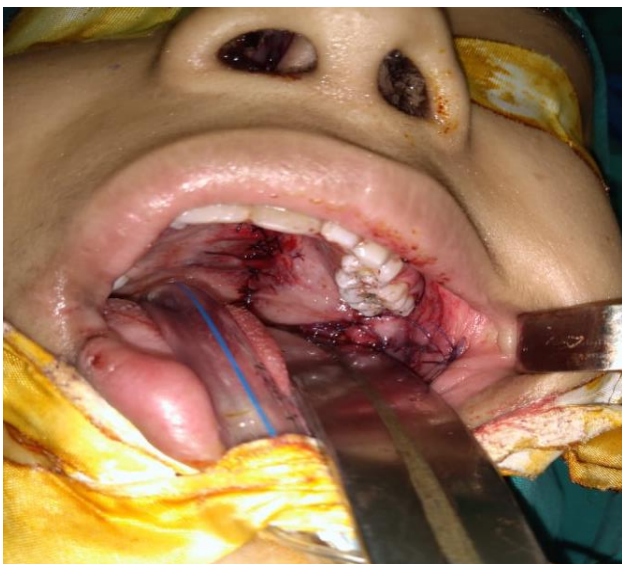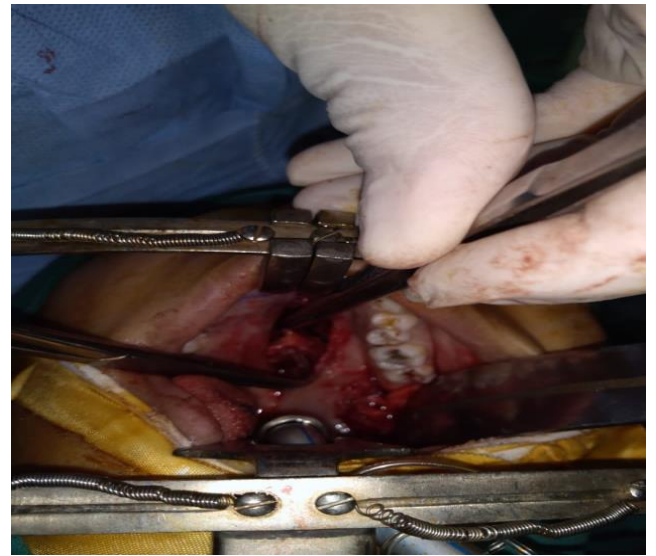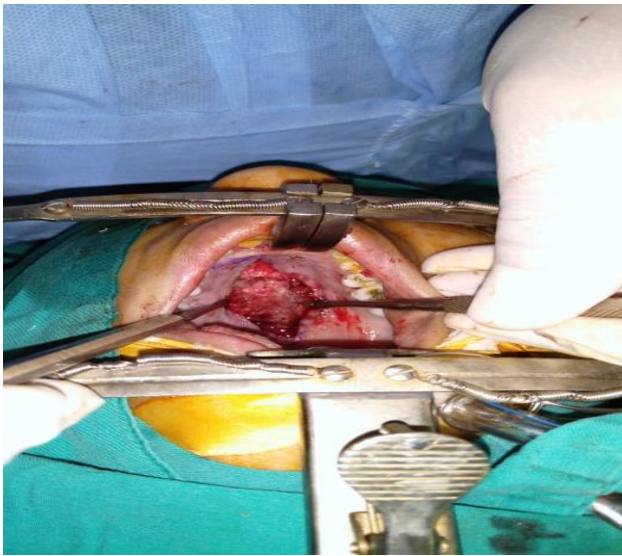
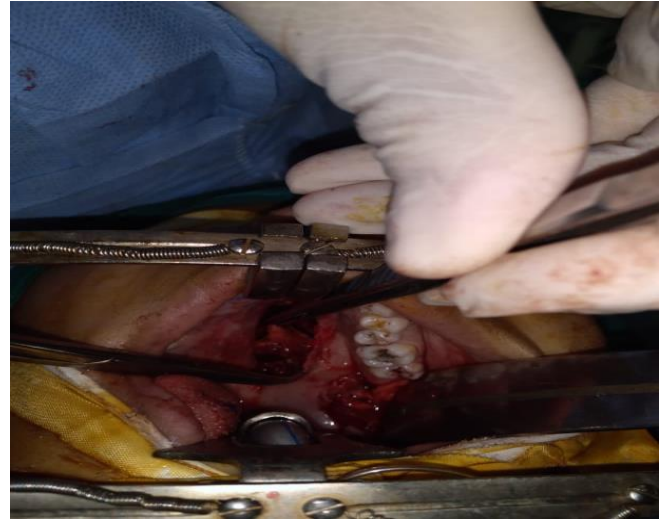
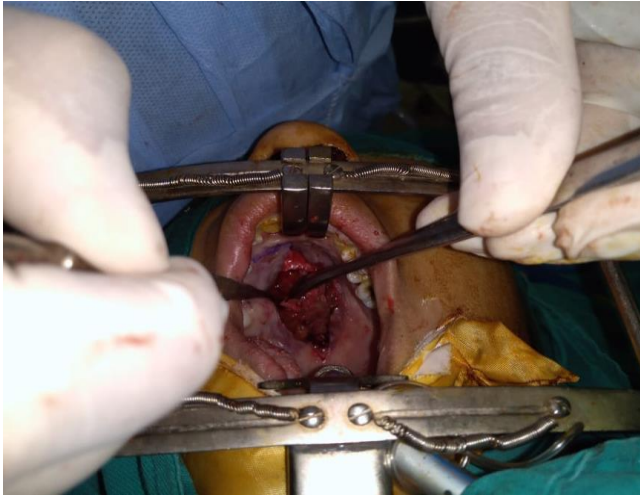


Fig. (3) Operative procedure with palatal incision ,dissection of the lesion .reconstruction of the palatal defect with buccinator rotational flap.

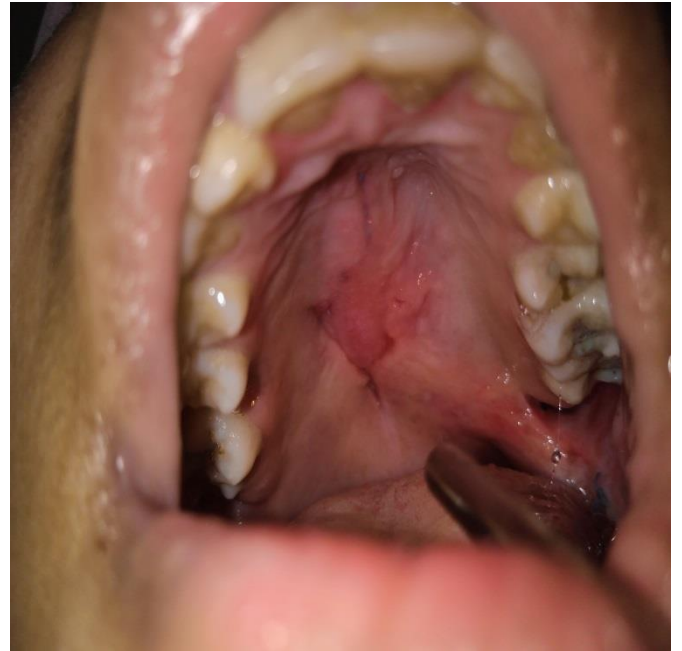
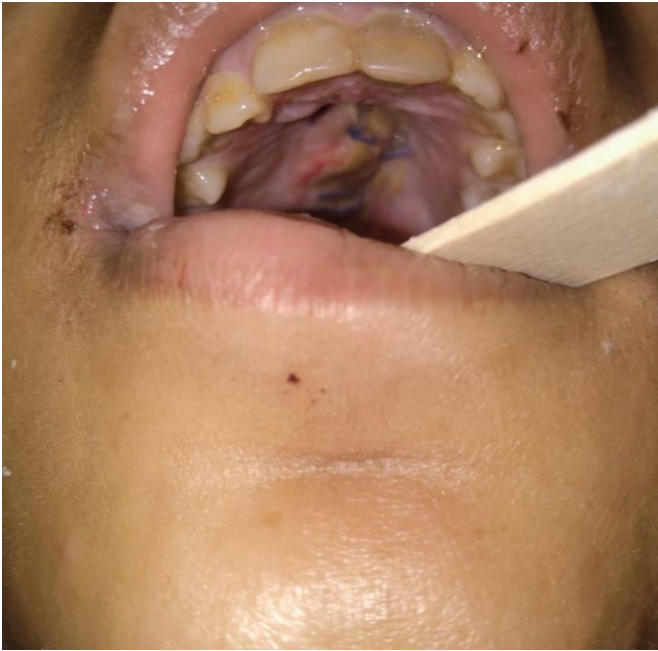
Fig. (4) Post-operative follow-up after 2weeks and 8 weeks with no recurrence with successful buccinator rotational flap.