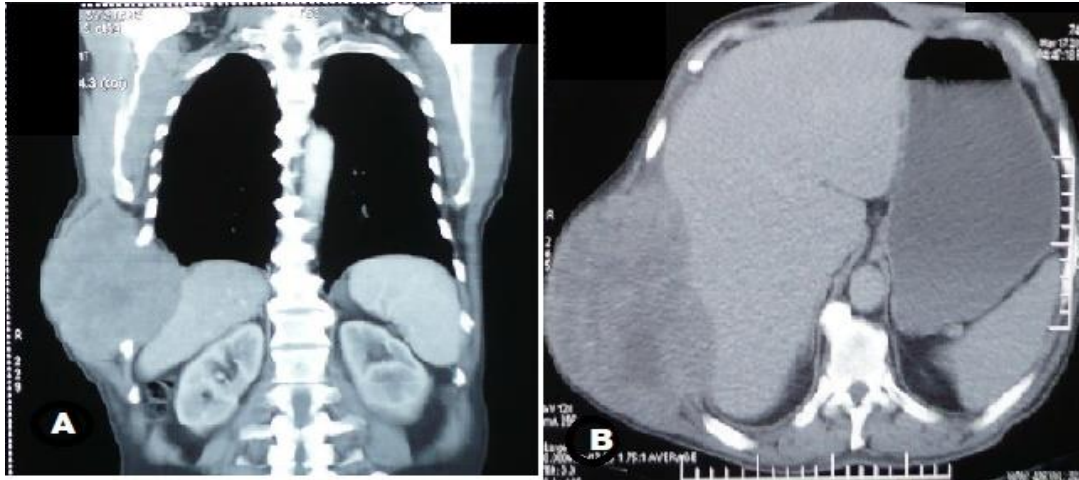


Figure 1: Preoperative CT chest; coronal (A) and axial (B) views showing right-side chest wall tumor



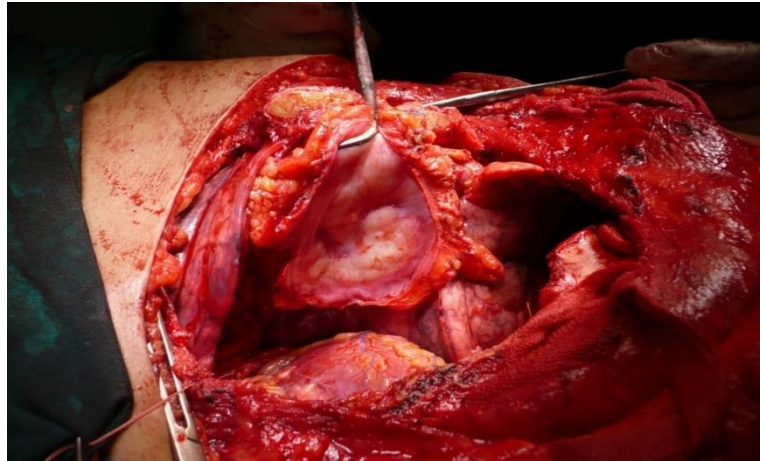


Figure 2: En-bloc resection of chest wall tumor with three ribs, wedge resection of the left lower lung lobe and lateral part of the pericardium

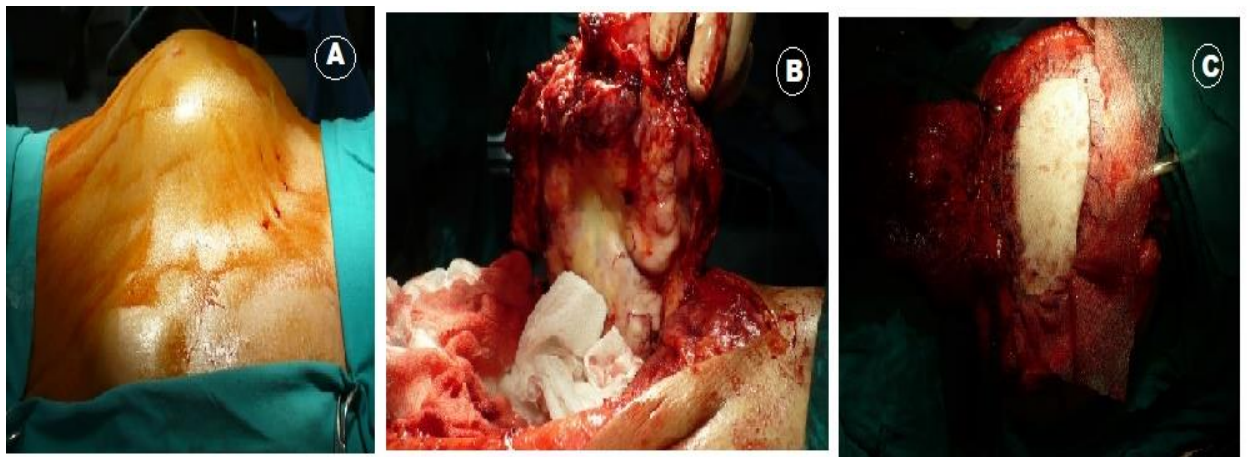


Figure 3: Operative resection of large chest wall tumor A) operative view, B) en-bloc resection of the tumor with the 7th, 8th, and 9th ribs, C) chest wall reconstruction using a methylmethacrylate-Prolene sandwich.

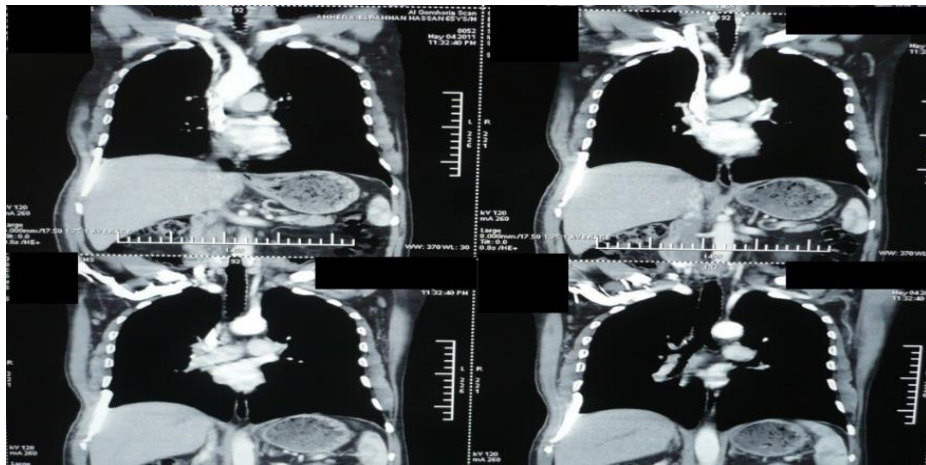


Figure 4: Postoperative CT scan after chest wall reconstruction

Statistical analysis