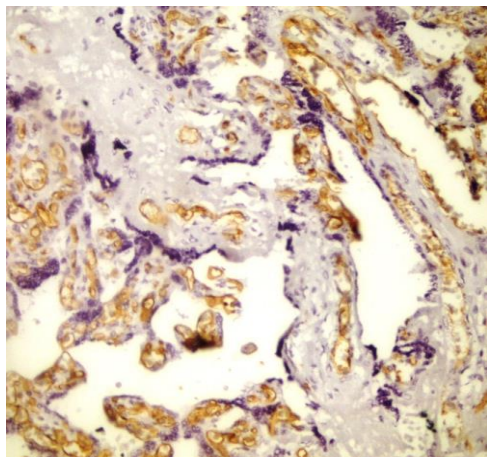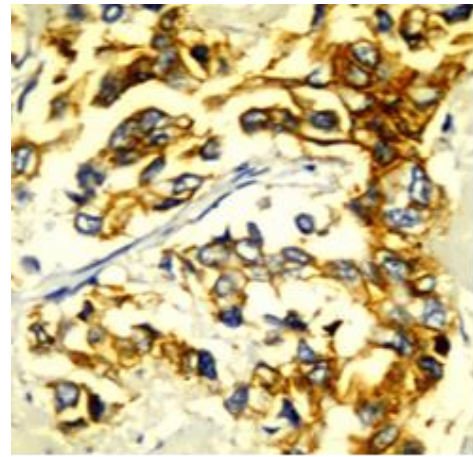
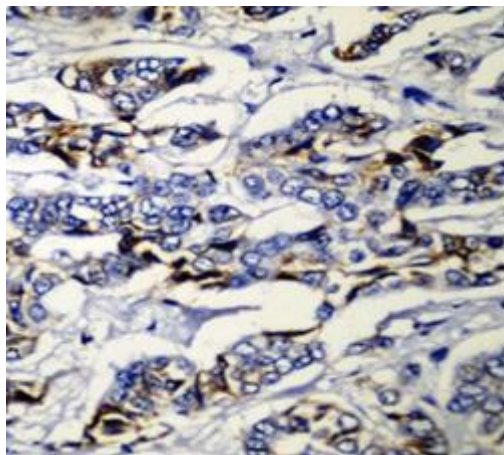


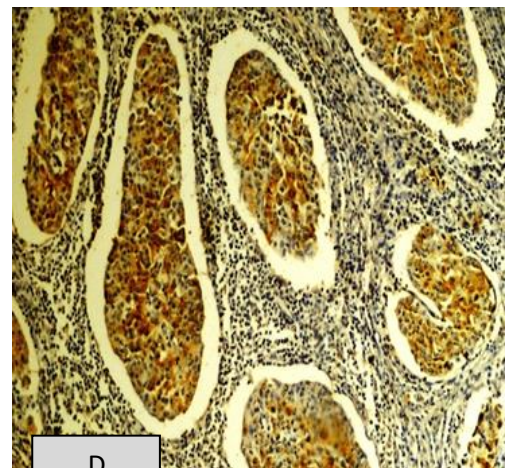
A



B

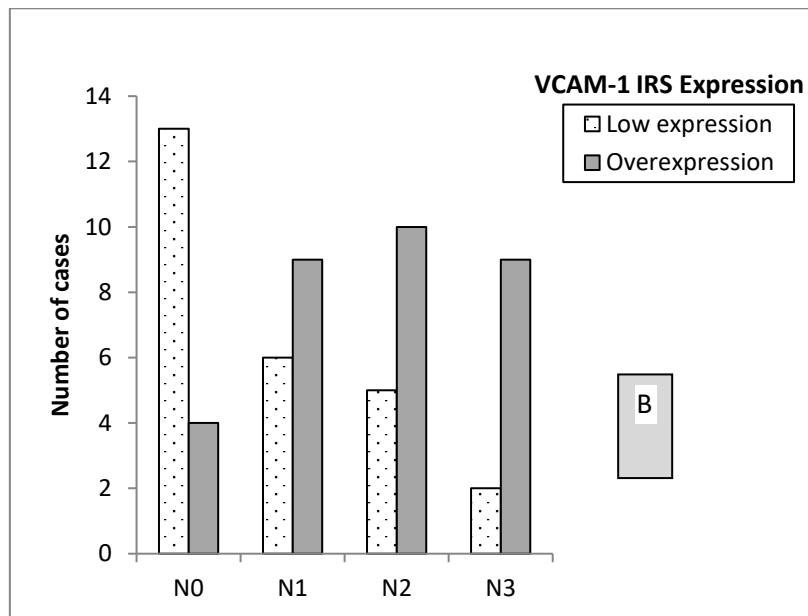
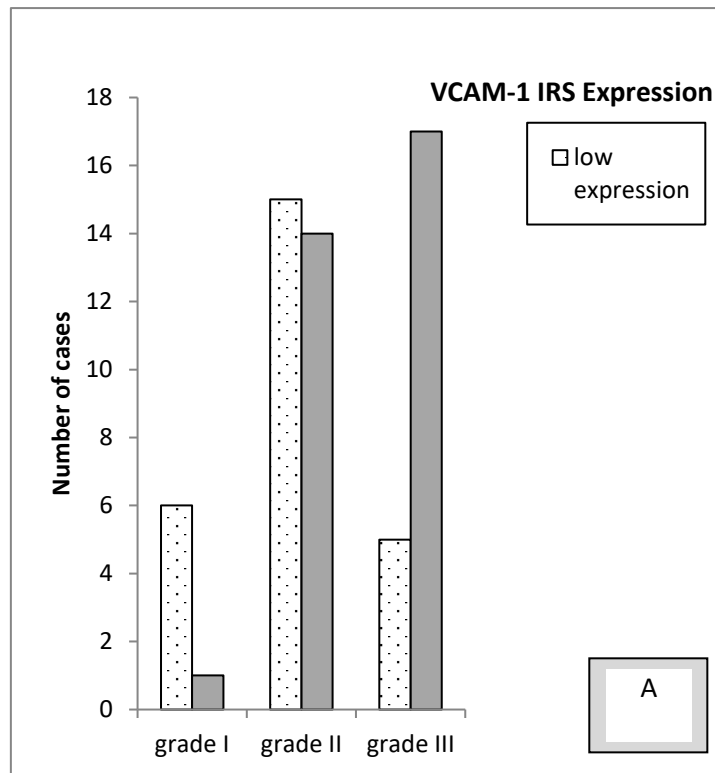


C



D

Figure 1: Representative IHC Staining of VCAM-1 **(A)** Placenta as positive control with VCAM-1 overexpression, **(B)** IDC-NST (grade III) showing cytoplasmic VCAM-1 overexpression, **(C)** IDC-NST (grade II) with –ve/low expression of VCAM-1, **(D)** Medullary carcinoma with cytoplasmic VCAM-1 overexpression. Original magnification is 200X in D and 400X in others.



Graph 1: Correlation of VCAM-1 Expression with Tumor Grade (A) and Lymph Node Status (B).

