

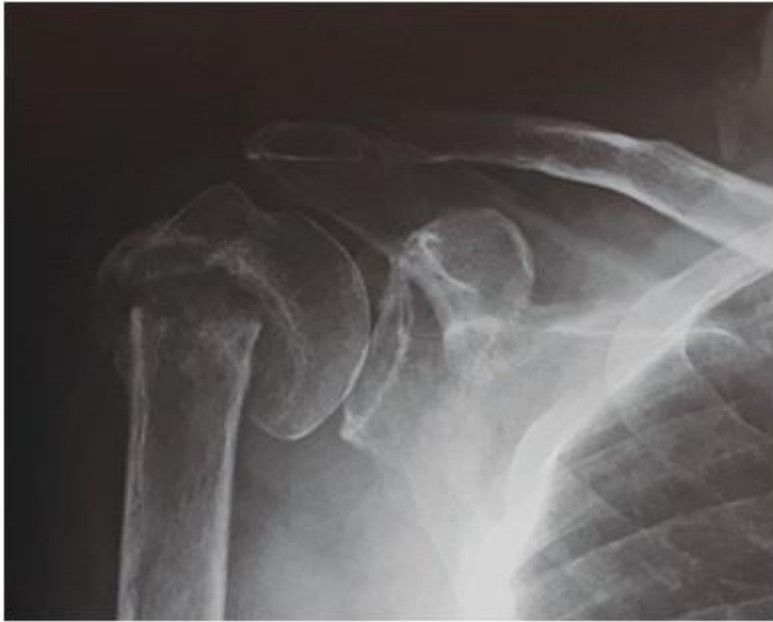

Fig 1. Nonunion case at 6 months follow-up with resorption of the surgical neck.

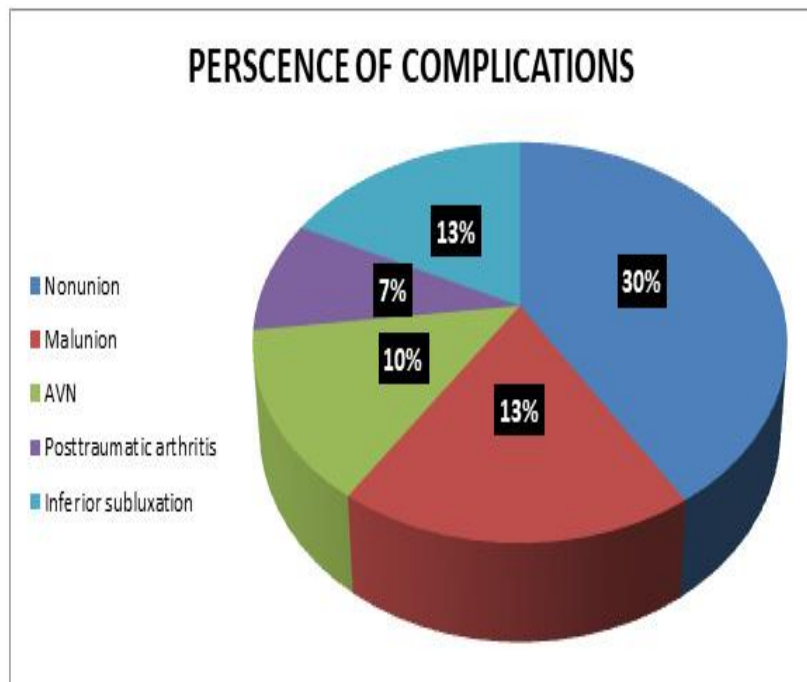


Fig 2.Percent of complications

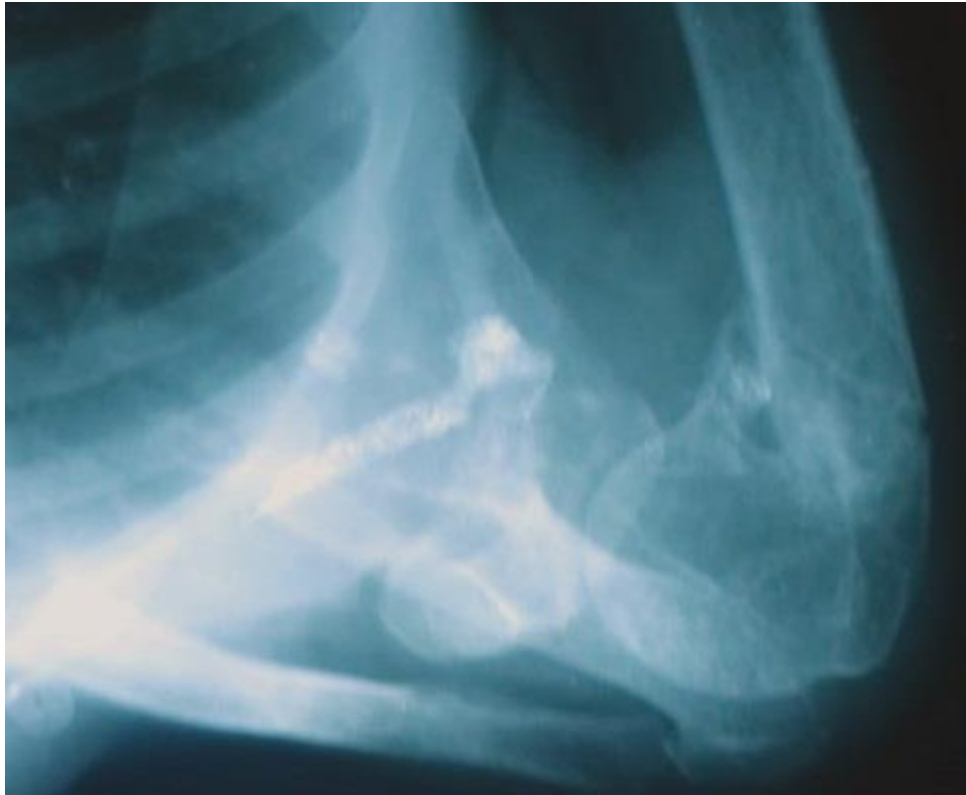

Fig 3.Malunioncase after 5 months follow up.

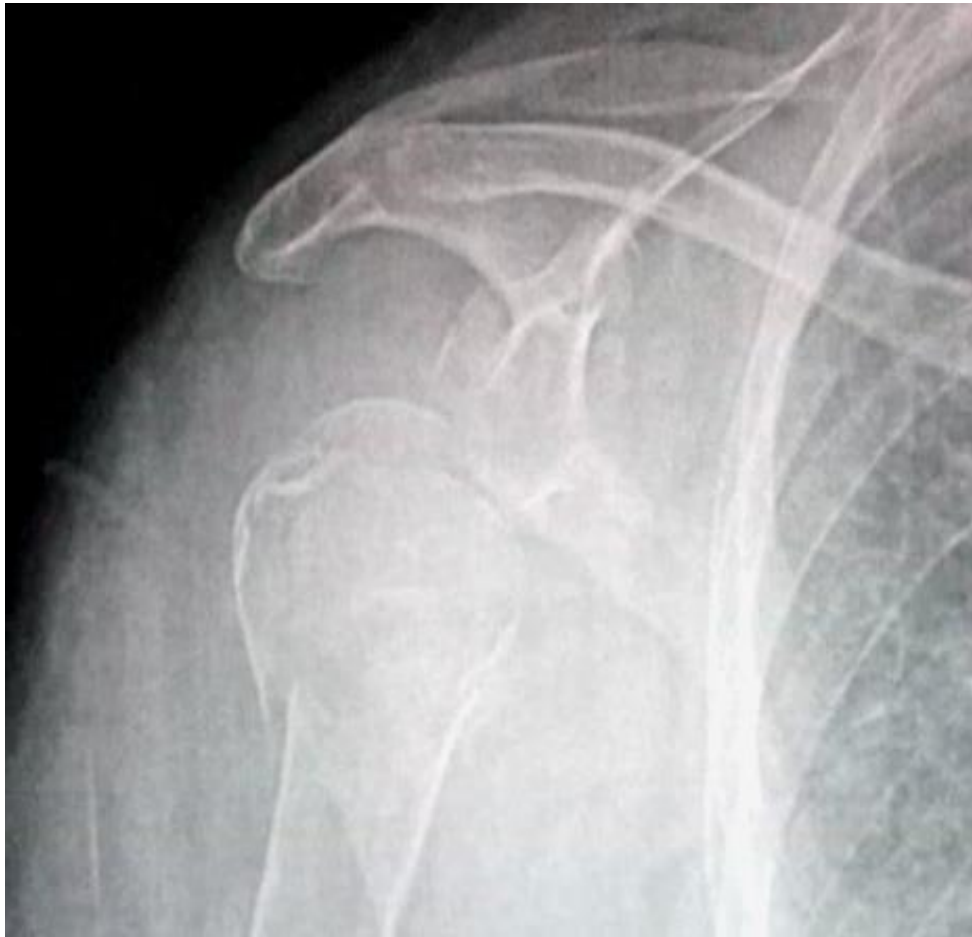


Fig 4.Inferior subluxation of the humeral head.