

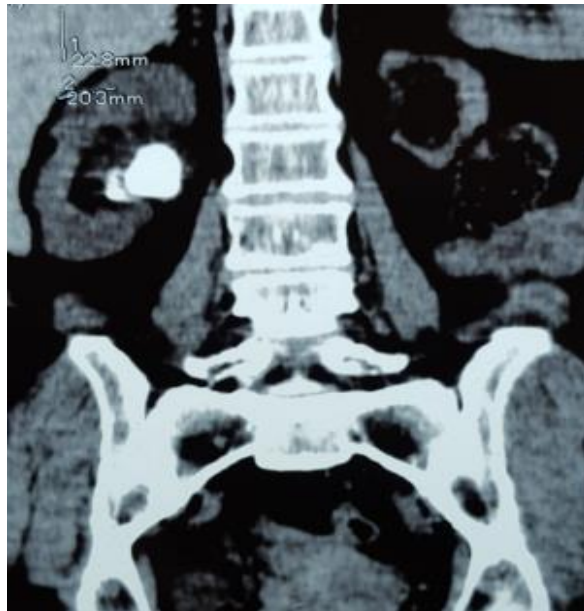Figure 1a: Female patient 56 year old with two radio-lucent stones pelvis and lower calyx only functioning right kidney. The left kidney is small sized and atrophic.

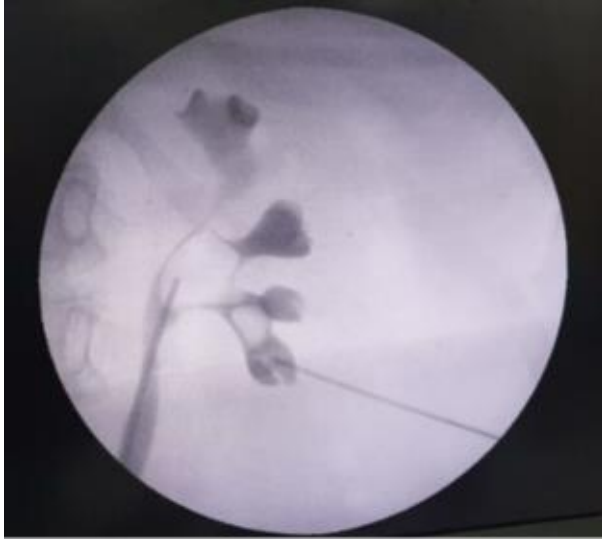


Figure 1b: Lower calyceal puncture after retrograde pyelogram under fluoroscopy

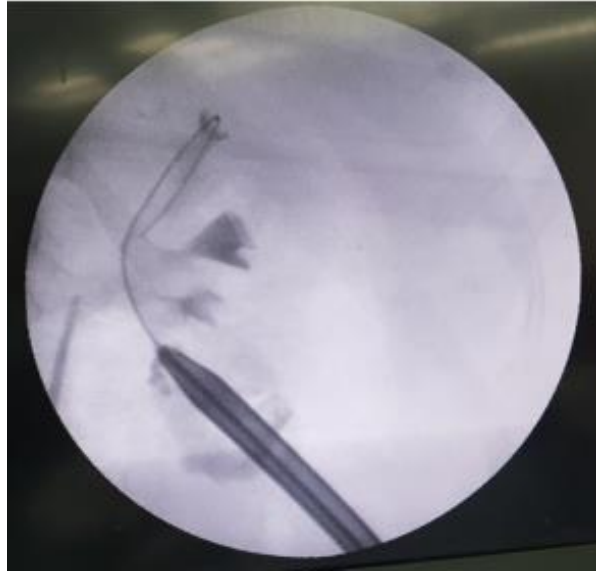


Figure 1c: Dilatation of the tract by Teflon dilators under fluoroscopy.

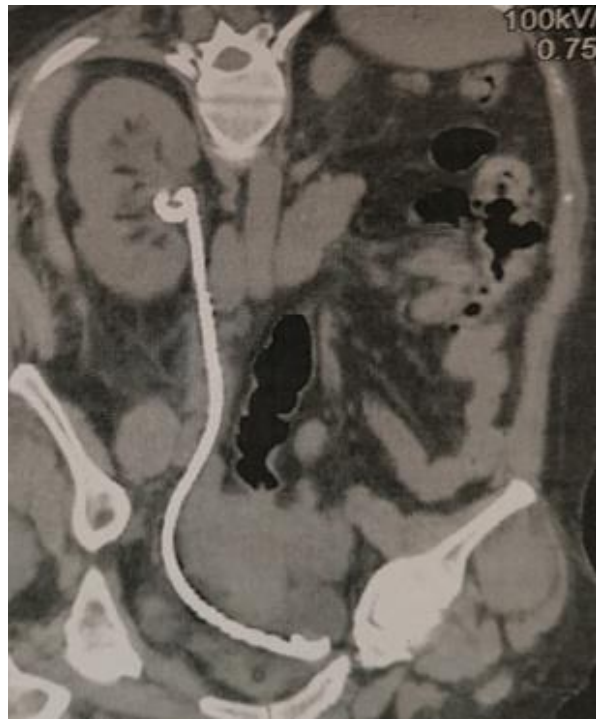


Figure 1d: Postoperative NCCT showing no residual stones and double J stent.