

Figure (1): Chest X-ray

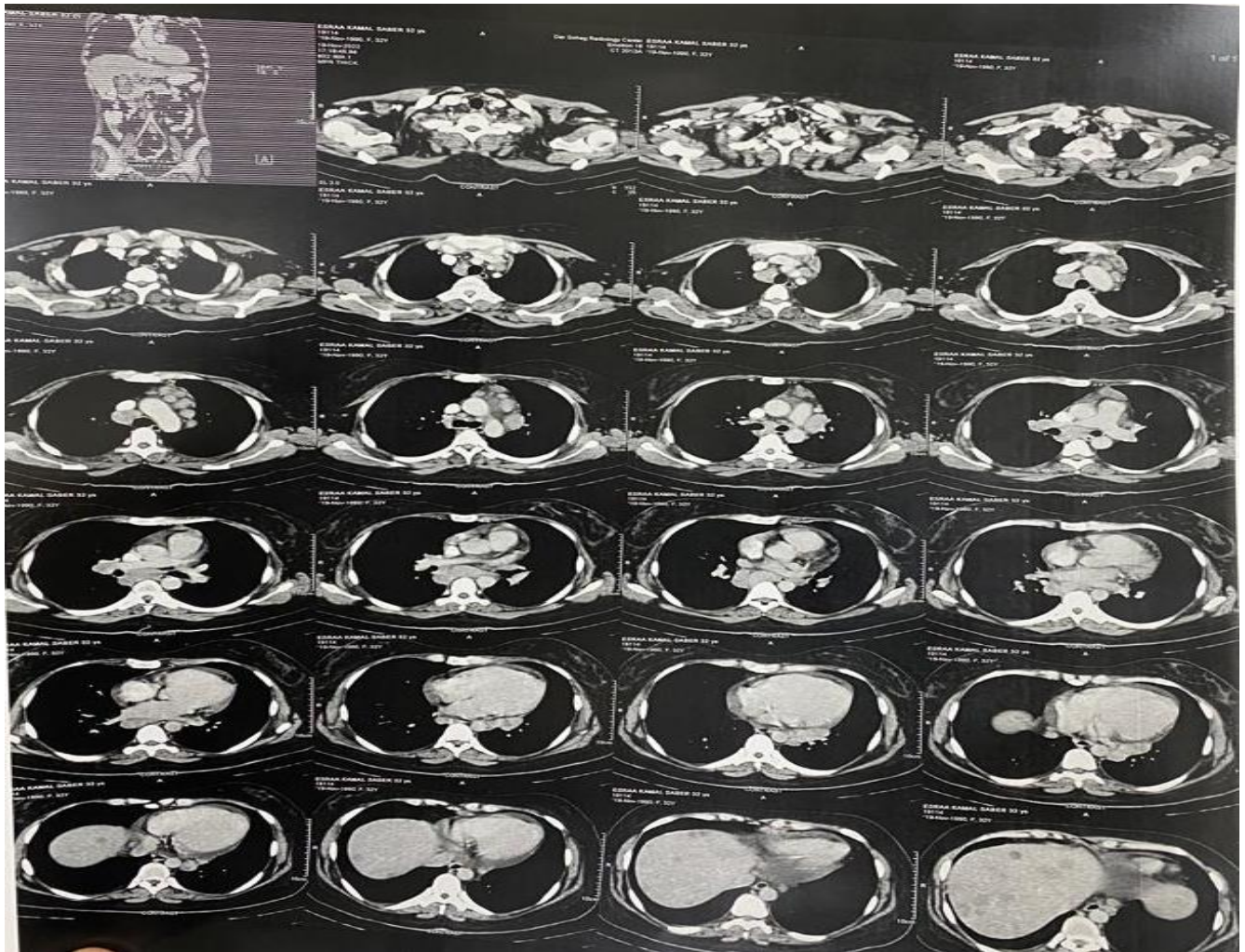


Figure (2): CE-MSCT chest.

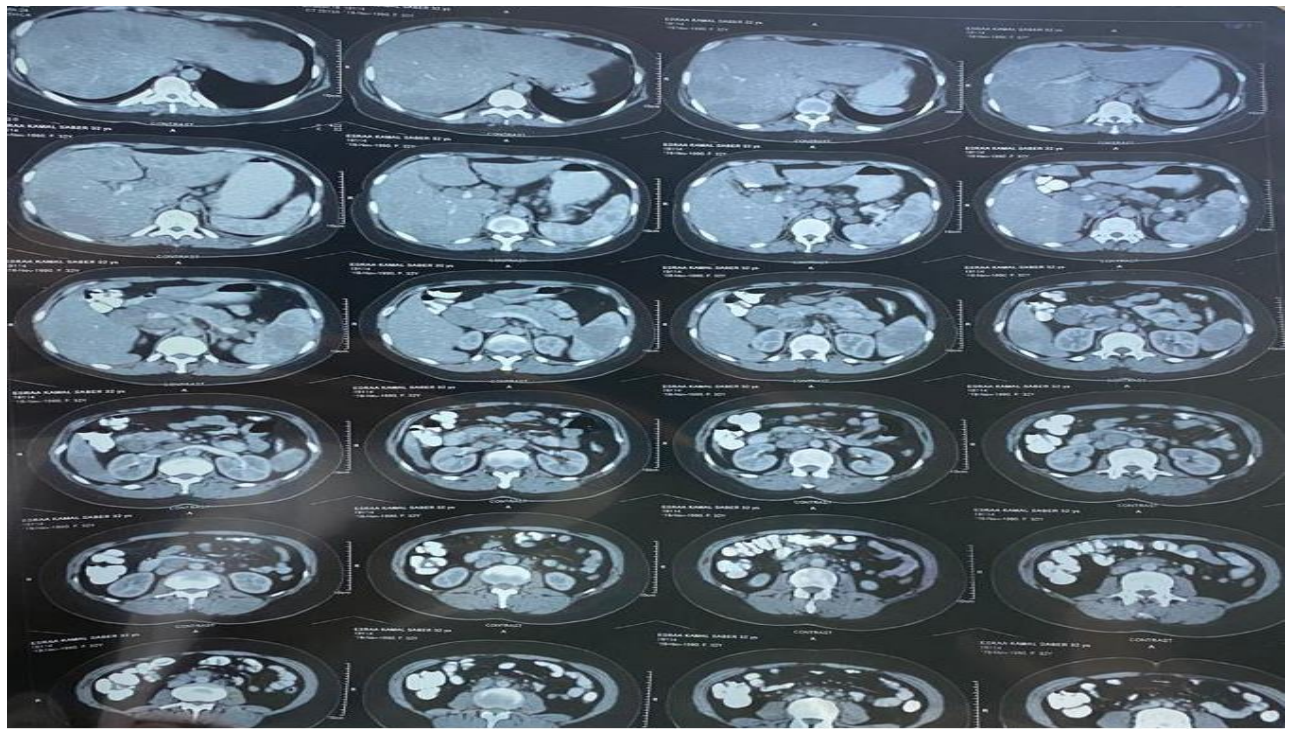


Figure (3): CE-MSCT abdomen and pelvis.

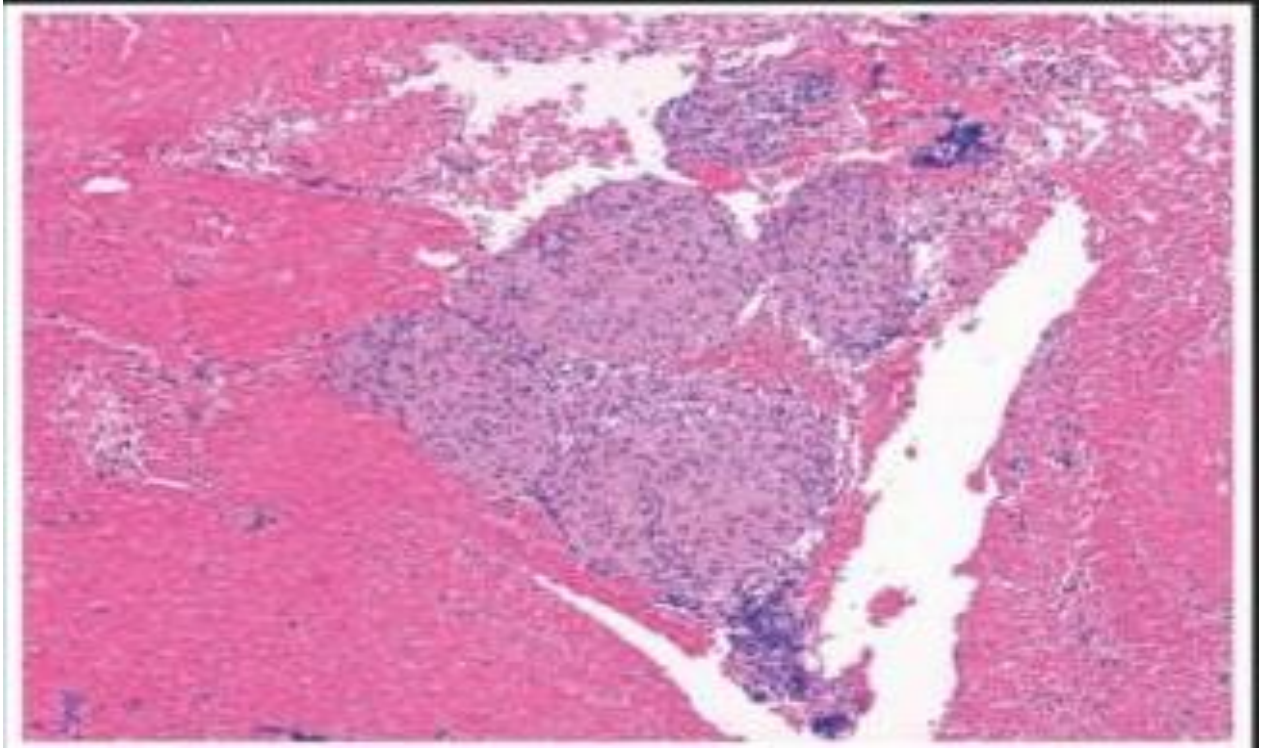


Figure (4): Non-caseating granulomatous inflammation with atypical lymphoid infiltrate

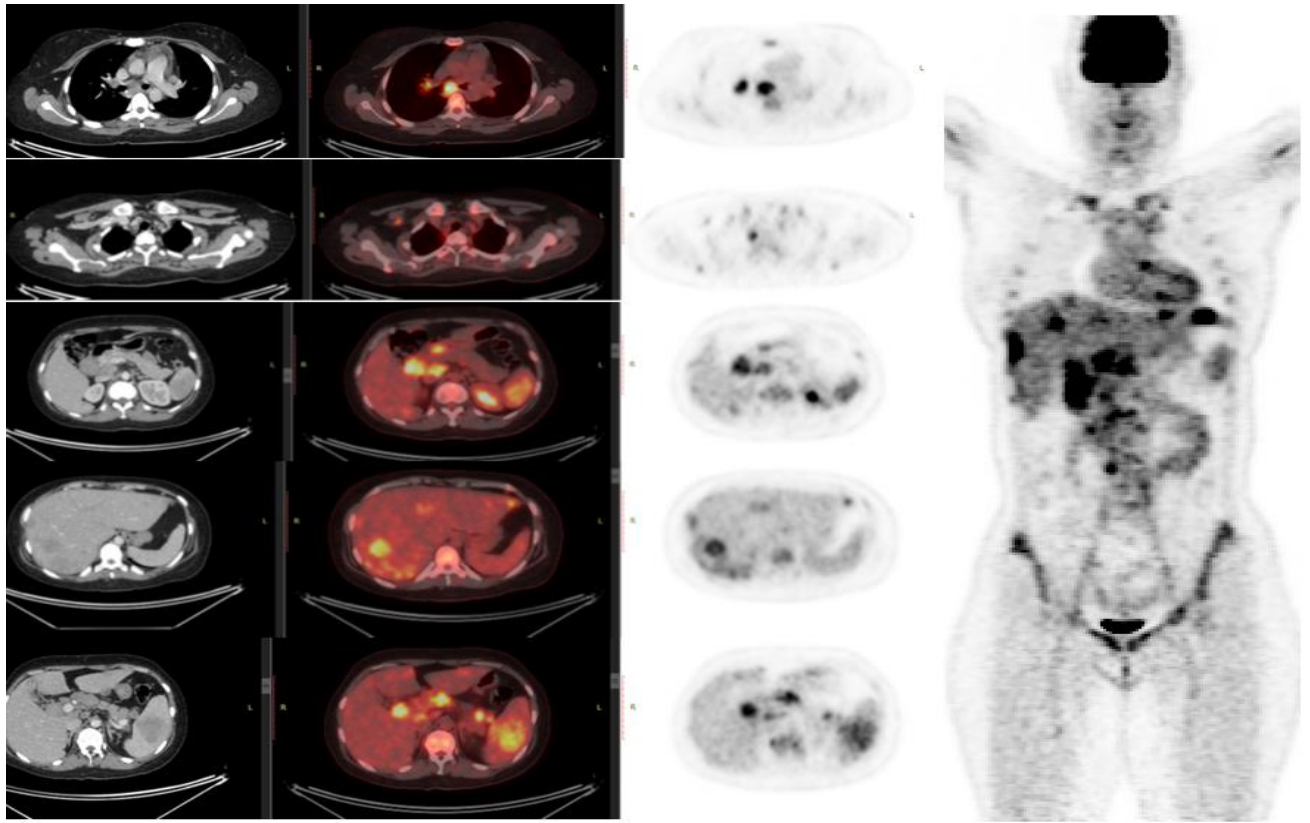


Figure (5): Whole body 18 F - FDG PET/CT