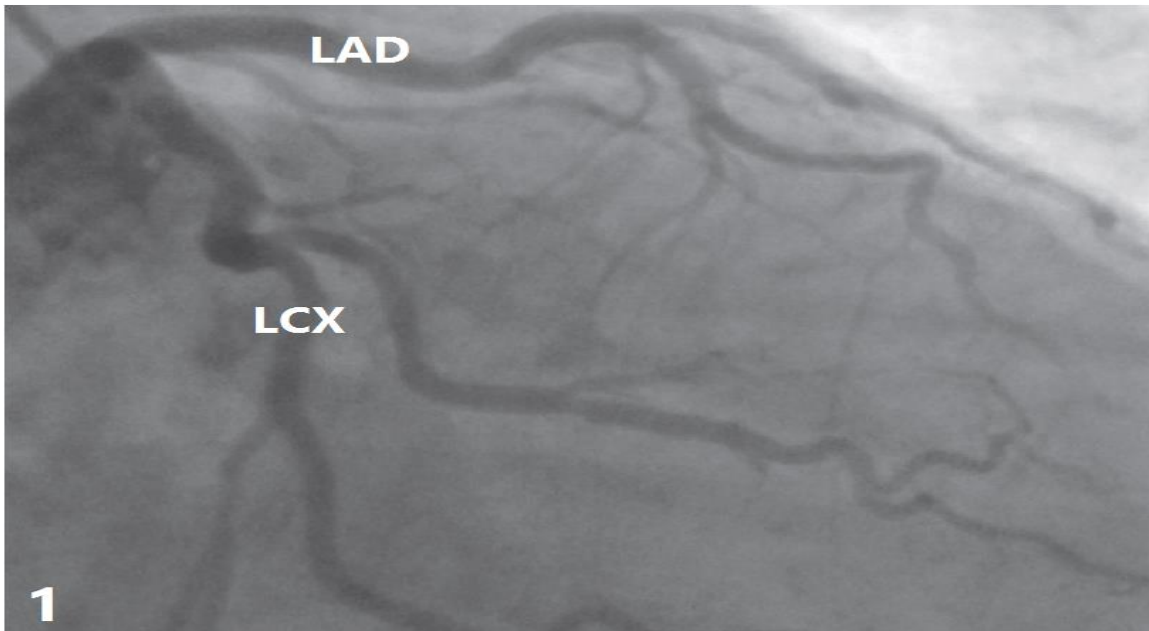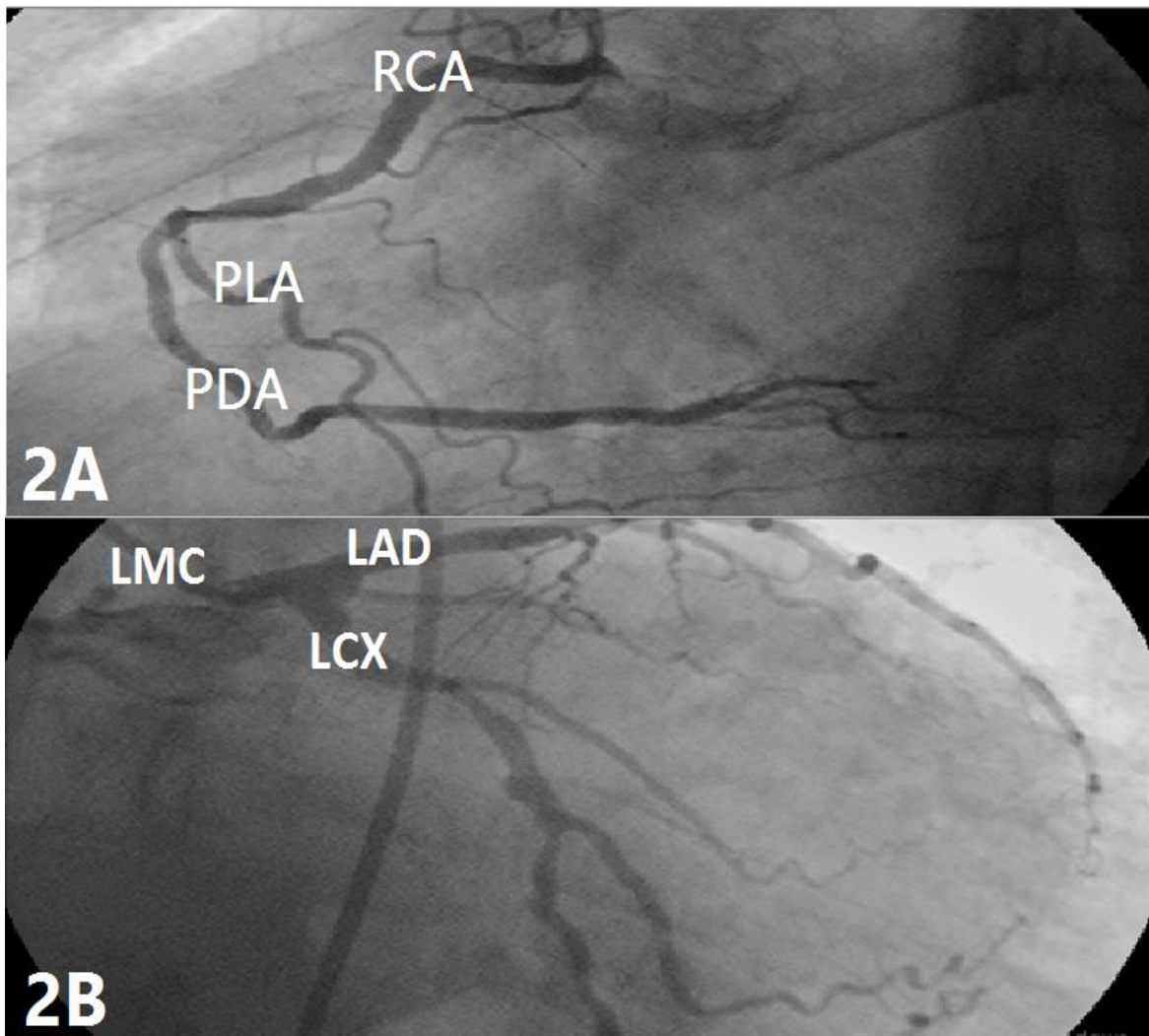
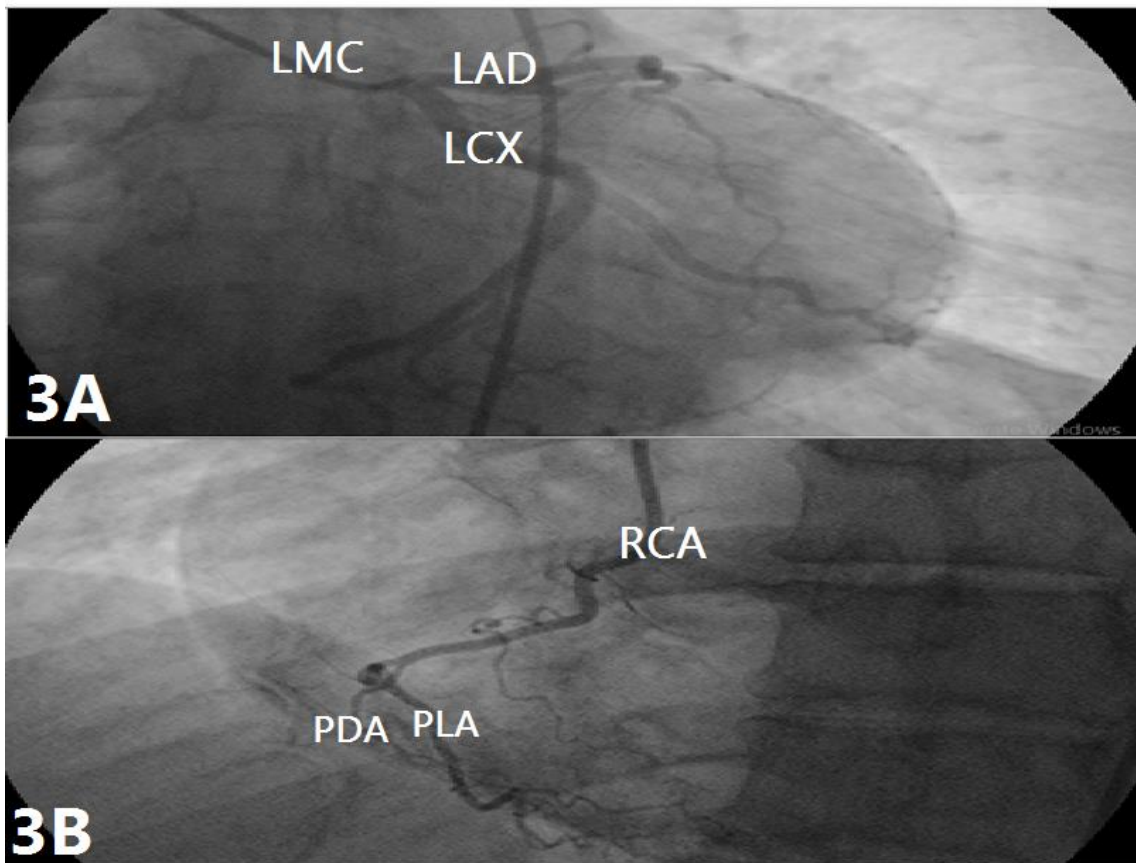




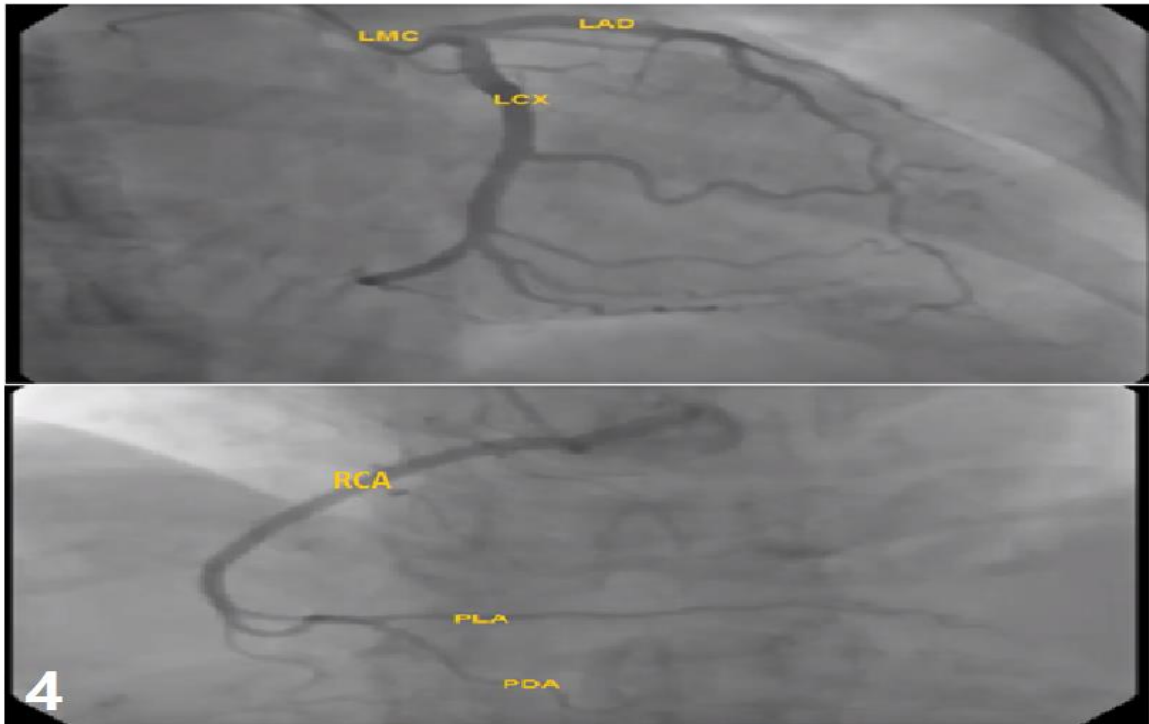
**Figure 1:** A coronary angiography of a 62 years old male, the right anterior oblique caudal view showing the separate origin of the left anterior descending. Artery and left circumflex artery from the left aortic sinus.



**Figure 2: 2A:** coronary angiography of 65 years male patient, left anterior oblique cranial view showing right coronary dominance. **2B:** Left anterior oblique caudal view of the same patient showing left main coronary, LAD, LCX.



**Figure 3:** **3A:** Coronary angiography of 66 years male, right anterior oblique caudal view, showing left dominance.  
**3B:** left anterior oblique caudal view of the same patient to show the right coronary.



**Figure 4:** Coronary angiography of 60 years old male, left anterior oblique cranial view showing that the posterior interventricular artery arises from the circumflex branch of left coronary artery and also from the right coronary artery (case of co-dominance).