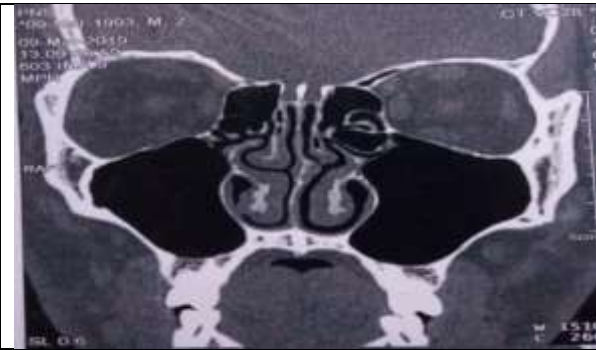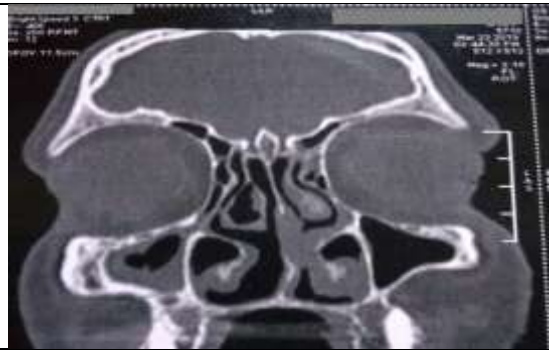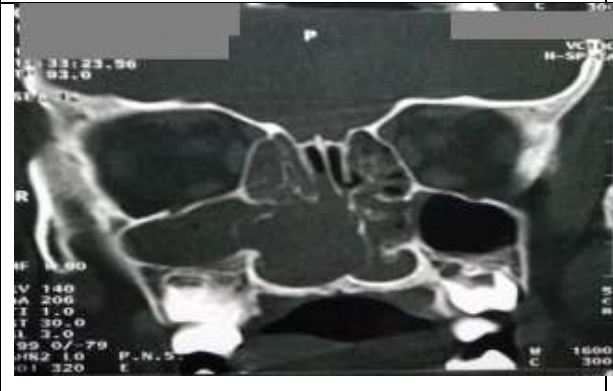


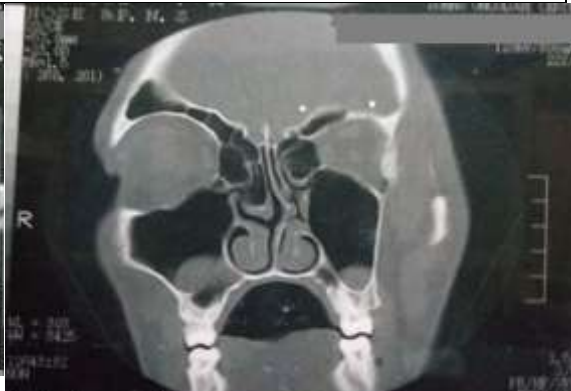CT nose & PNS, coronal section showing C-shaped DNS to the left with bilateral ITH.



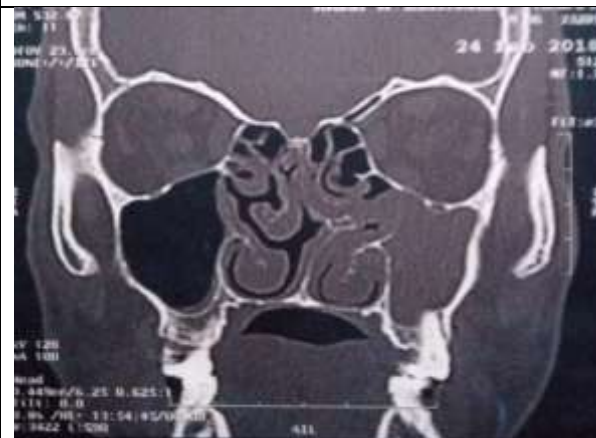
CT nose & PNS, coronal section showing, C-shaped DNS, unilateral right middle CB



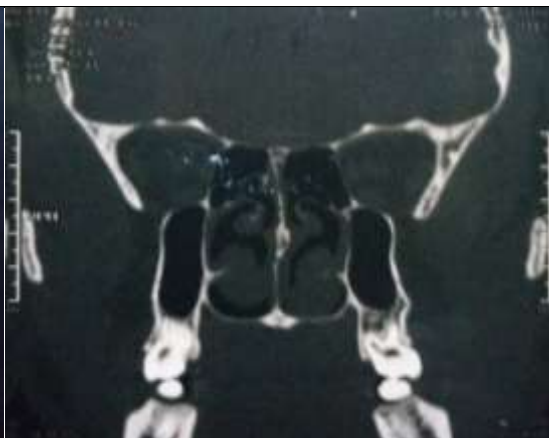
CT nose & PNS, coronal section showing nasal polyps and DNS to the left



CT nose & PNS , coronal section, showing , C-shaped DNS to left, right middle CB and bilateral ITH



CT nose & PNS, coronal section showing C-shaped DNS to the left with chronic sinusitis



CT nose & PNS, coronal section showing bilateral ITH