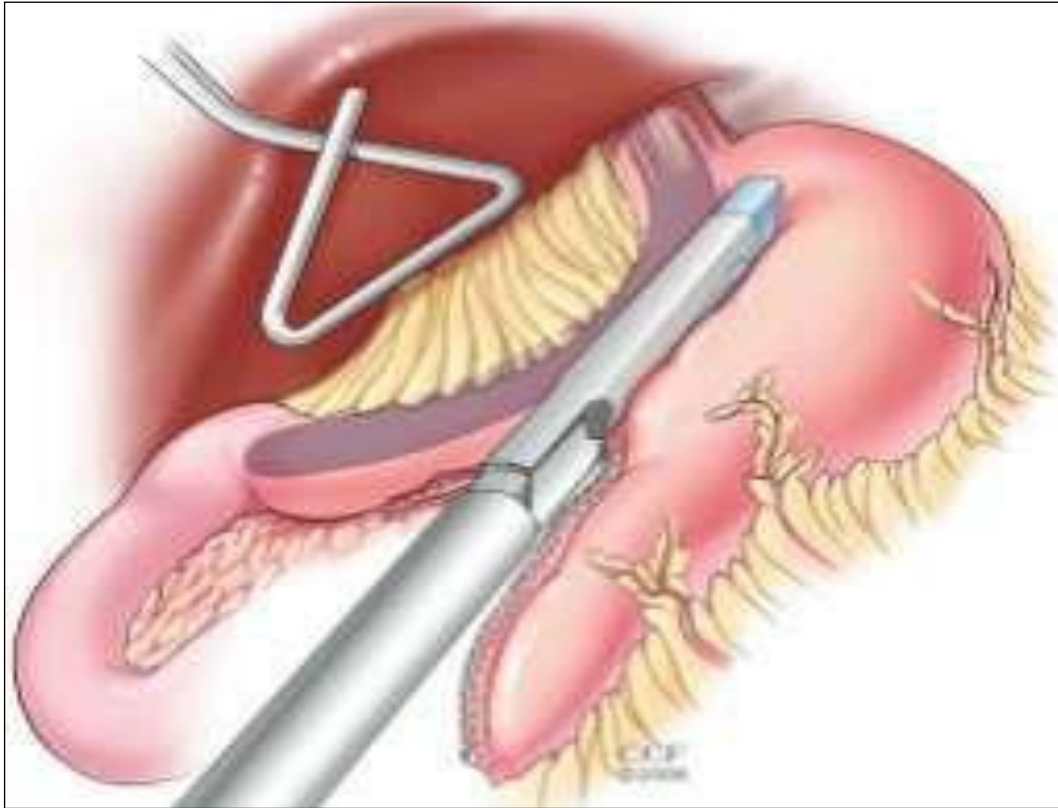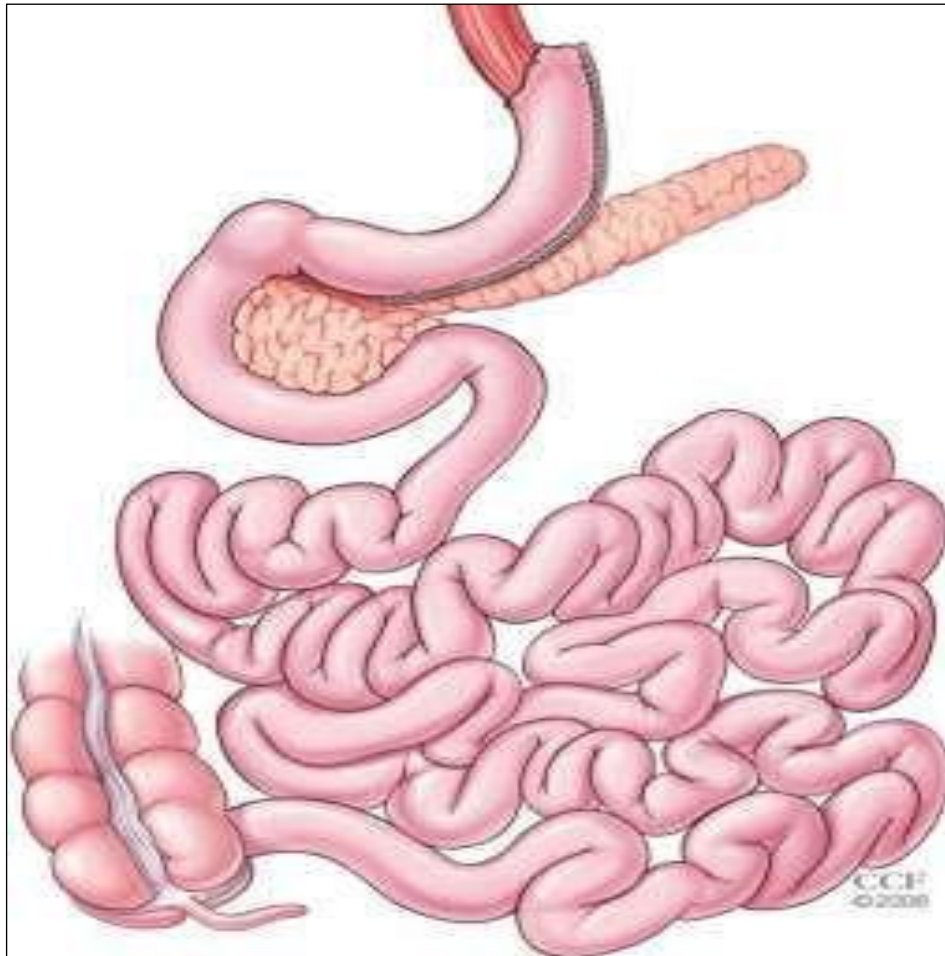


**Figure 1: Laparoscopic sleeve gastrectomy. The stapler is fired successively from the antrum to the angle of His adjacent to an intragastric bougie <sup>(14)</sup>**



**Figure2: Completed sleeve gastrectomy demonstrating a tubularized stomach** <sup>(15)</sup>

### Roux-en-Y Gastric Bypass (RNY)

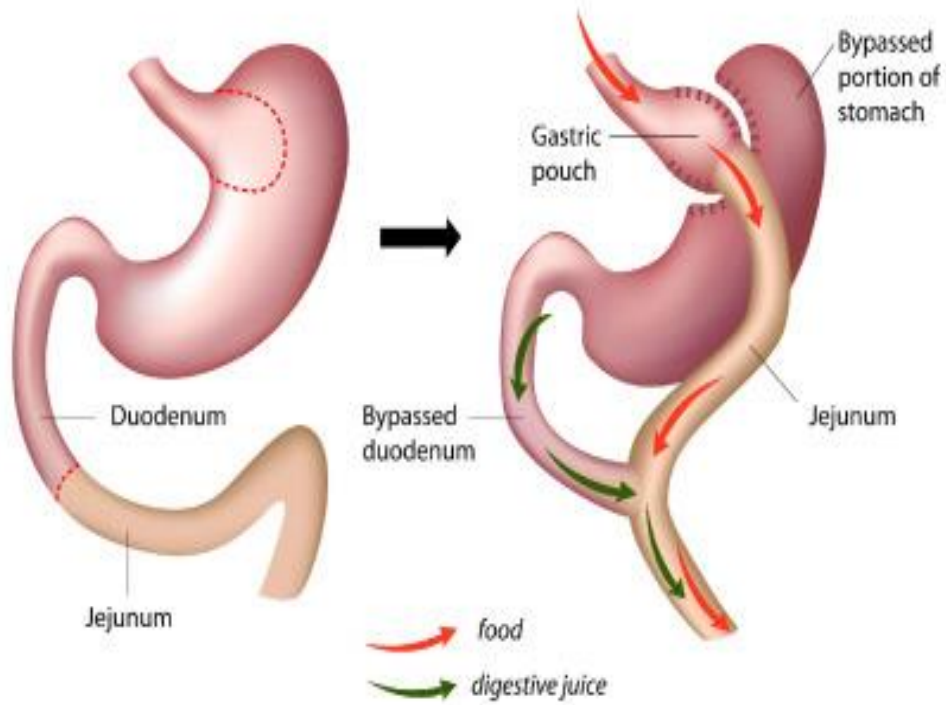


Figure 3: ROUX-EN-Y Gastric Bypass (RYGB) <sup>(19)</sup>