



The Possible Ameliorative Effect of Vitamin C Against Amoxicillin-Clavulanic Acid Toxicity in the liver of Adult Male Albino Rats

Hanaa Mohammed¹, Ahmed Talat Galal²,
Mohammed Abdel Rahman¹, Yasmeen Bander Hosny¹.

1. Department of Human Anatomy and Embryology, Faculty of Medicine, Sohag University, Sohag, Egypt.

2. Department of Human Anatomy and Embryology, Faculty of Medicine, Assiut University, Assiut, Egypt

Abstract:

Background: Amoxicillin/clavulanic acid (AC) is used to treat a variety of bacterial infections, most frequently linked to drug-induced hepatotoxicity. Vitamin C is a necessary, water-soluble micronutrient serves as an antioxidant and cofactor for several enzymes,

Aim of the work: Our research aimed to study the potential Ameliorative role of vitamin C against the amoxicillin- clavulanic acid induced hepatotoxic effects on the liver of the adult male albino rats.

Materials and methods: 30 adult albino rats were used. The animals were equally divided into three groups, each of them consisting of 10 rats. **Group I:** "control" Animals were not subjected to any treatment. **Group II:** were given Amoxicillin-Clavulanic Acid. **Group III:** were given Amoxicillin-Clavulanic Acid and Vitamin C treated it. At the end of the experiment, blood samples and livers were collected for biochemical and histological study.

Results: Administration (AC) had apparent hepatotoxic effects in the form of elevations in blood liver enzymes, disruption of the antioxidant capacity of liver tissue. Co-administration of Vitamin C could reduce all the biochemical and histological effects of AC.

Conclusion: Vitamin C has protective and therapeutic effects on AC-induced liver damage in rats.

Keywords: liver, Amoxicillin/clavulanic acid, Vitamin C, Rats

DOI : 10.21608/smj.2024.256388.1437

*Correspondence : yasmeenbander95@outlook.com

Received: 07 January 2024.

Revised: 19 February 2024.

Accepted: 19 January 2024.

Published: 01 May 2024.

Introduction:

Adult liver weighs about 1,500 grammes (2.5% of total body mass), making it the second heaviest organ after the skin. It occupies the upper epigastrium, right hypochondrium, and right hypogastrium in the right upper abdominal quadrant. ⁽¹⁾ Many

medicines and their reactive metabolites are metabolized by the liver. ^(2,3)

Amoxicillin is a commonly recommended antibiotic for treating and preventing gram-negative bacterial infections, particularly when combined with potassium clavulanate. In spite of being the

most widely used medication in clinical medicine and amoxicillin-clavulanate closely linked to cholestatic liver injury and drug-induced hepatic-ellular injury. (4,5)

Vitamin C is an antioxidant vitamin soluble in water found in the diet. Its reducing or electron donor properties make it a necessary cofactor for many biological reactions. VC greatly reduces reactive oxygen and nitrogen species that can damage macromolecules like lipids, proteins, and DNA. (6,7)

Aim of the work: our work aimed to study the Ameliorative role of vitamin C against the amoxicillin- clavulanic acid – induced hepatotoxic effects on the liver of the adult male albino rats.

Material and methods:

30 adult male albino rats their weight range from 200-250g were used.

Group A (control): Animals were not subjected to any treatment.

Group B (Amoxicillin-clavulanic Acid treated Group): Animals were given amoxicillin-clavulanate in a dose of 30 mg/kg body weight orally via gastric gavage every day for successive 7 days. (3)

Group C (Amoxicillin- clavulanic Acid and Vitamin C treated group): Animals were given amoxicillin-clavulanate in a dose of 30 mg/kg body weight orally via gastric gavage every day for successive 7 days (3) and Vitamin C in a dose of 100 mg/kg body weight of vitamin C orally via gastric gavage every day for successive 21days. (8)

Chemicals:

GlaxoSmithKline Egypt produced film-coated tablets containing 1000 mg of Augmentin (a combination of Amoxicillin/clavulanic acid) that were obtained from a local pharmacy. Vitamin C capsules from GlaxoSmithKline Egypt (500 mg) were bought from a local pharmacy.

Sample Collection:

Inhaling 1.1% isoflurane sedated the animals. (9) A needle was inserted through the orbit's medial angle to take blood from the retro-orbital venous plexus. The cervical decapitation method was used to

ethanized all rats, the anterior abdominal wall was dissected, and liver samples were extracted after blood samples. (10)

Biochemical analysis:

▪ **Evaluation of the liver function:** The serum was separated by centrifuging blood samples at 3000 rpm for 10 minutes. After keeping the serum at -20°C, AST, ALT, ALP, and LDH levels were measured. (11)

▪ **Assessment of oxidative stress in liver tissue:** To measure oxidant/antioxidant status, liver tissues from each group were frozen at -80°C and homogenized for MDA and GSH levels. (12)

Light microscopic study:

At the end of the experiment, rats were given ether anesthesia and then saline and the proper fixator (10 percent formalin) were introduced to them. The abdomen of the control and treatment animals were opened, the livers were quickly extracted, preserved in 10% formalin, and cut into 4-6 µm-thick paraffin slices for light microscopic examination

Statistical analysis:

All data was provided as Mean ±SD (mean standard deviation). The independent sample T-test was used to compare the means of these variables between groups. In the end, the following analysis of the significance was done using the p-value, or degree of significance:

P > 0.05 (NS) → non-significant difference.

P ≤ 0.05 (*) → Significant difference.

P ≤ 0.02 (**) → High significant difference

Results:

A- Histopathological results:

Light microscopic Results:

Hematoxylin and Eosin stain:

Group A (control): sections of liver revealed its normal architecture. The hepatic lobule was formed of a central vein and plates of hepatocytes radiating from it. The hepatocyte appeared polyhedral with spherical vesicular nuclei in the center. Some hepatocytes had two nuclei, acidophilic cytoplasm with basophilic granules. Blood sinusoids appeared between hepatocytes and were lined with flat

endothelial cells and von Kupffer cells (**Fig1A&B**). At the periphery of the hepatic lobule are portal areas (triad) with branches of the portal vein, hepatic artery, and bile duct. (**Fig1B**).

Group B (Amoxicillin – clavulanic acid treated): light microscopic examination of liver sections following AC treatment revealed distortion of the liver architecture around the central veins (**Fig1C**) and portal tracts (**Fig1D**) with diffuse areas of faintly stained hepatocytes. Infiltration of inflammatory cells surrounding central veins and portal tracts. Compared to the control group, the portal area showed a dilated and congested portal vein (**Fig1C**) Between the vacuolated hepatocytes, congested, dilated blood sinusoids were observed. Some hepatocyte nuclei were heavily stained. Other hepatocytes appeared with their cytoplasm vacuolated. Numerous small fragmented pycnotic nuclei were numerous around the central vein and portal tract. (**Fig1C&D**)

Group C (Amoxicillin -clavulanic acid and Vitamin C) treated Group: The liver of the rats in group III showed some improvement when compared with those in group II. The hepatocytes were arranged in radiating cords around the central veins and portal tracts (**Fig1E&F**) Some hepatocytes appeared normal, while others showed vacuolation and infiltration of inflammatory cells around central veins and portal tract. In the portal area, there was mild dilated congested portal vein (**Figure1E**) Although the blood sinusoids had recovered, some had mildly dilated (**Fig1F**).

Masson trichrome stained sections:

Group A (control I) and Group C (Amoxicillin - clavulanic acid and Vitamin C treated): showed little collagen fiber distribution around the portal tracts and central vein. There also a few collagen

fibers between hepatocyte cords. (**Fig2A&B**) and (**Fig2E&F**).

Group B (Amoxicillin – clavulanic acid treated): in the portal area, dense strands of collagen fibers were observed radiating from the central veins and extending between hepatocytes, blood vessels, and the bile duct (**Fig2C&D**).

NF-KB immuno-stained sections:

Group A (control) and Group C (Amoxicillin - clavulanic acid and Vitamin C treated): showed negative cytoplasmic NF-kB p65 reactivity around portal tract and central vein (**Fig1A&B**) and (**Fig 3E&F**).

Group B (Amoxicillin – clavulanic acid treated): showed positive in cytoplasmic NF-kB p6 reactivity around portal tract and central vein (**Fig3C&D**).

B- Biochemical results:

i- The liver function enzymes: Group B had significantly higher serum levels of all four tested liver enzymes compared to the control group: ALT, AST, ALP, and LDH. there was no significant difference between group C and control groups, group C's mean levels of these enzymes were considerably lower than those of group B. (**Table 1, Fig 4**).

ii- Effects on the oxidant/antioxidant status markers: When comparing groups, A and B, the current study found that group B's GSH decreased and MDA increased . In comparison to group B, group C had lower MDA and higher GSH levels, group C's MDA concentration was significantly greater and its GSH levels were not significantly different from those of the control group. (**Table 1, Fig 5**)

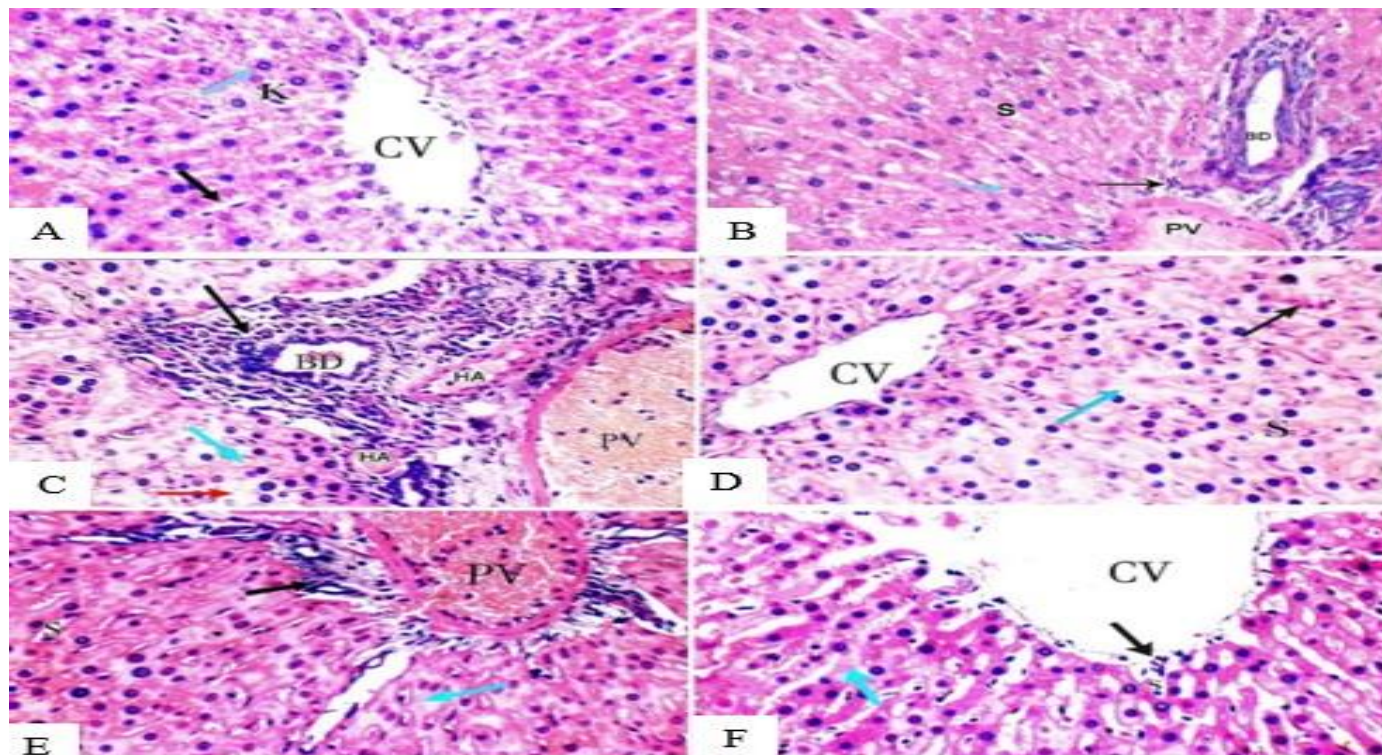


Figure 1. A photomicrograph of A: Liver section of a control (**group A**) showing central vein (CV) surrounded by plates of hepatocytes radiating from it (blue arrow) separated by blood sinusoids (S) lined with endothelium cells (black arrow). Note: Von Kupffer cells (K) (**H&E X 200**).

B: Liver section of the control (**Group A**) showing Portal tract containing (hepatic artery (HA), portal vein (PV) and bile duct (BD) (black arrow) surrounded by plates of hepatocytes with vascular nucleus (blue arrow) separated by blood sinusoids (S) (**H&E X 400**).

C: liver Section of AC treated (**Group B**) showing distortion of arrangement of liver plates around the portal tract. Inflammatory cells around it (black arrow), Most hepatocytes are vacuolated (red arrow). Only a few hepatocytes appear normal, dilated congested Portal Vein (P.V) and dilatation in blood Sinusoids (S) with hemorrhage in it (blue arrow) Note: Hepatic artery (HA), Bile duct (BD)) (**H&E X 400**).

D: liver section of AC treated (**Group B**) showing distortion of the arrangement of liver cords around the central veins (CV), Most hepatocytes are vacuolated (blue arrow). Only a few hepatocytes appear normal, dilatation in blood Sinusoids (S) with hemorrhage in it (black arrow) (**H&EX400**).

E: Liver section of Vitamin C treated (**Group C**) showing portal tract surrounded by normal hepatocytes. minimal inflammatory cells infiltration (black arrow) and vacuolation of cytoplasm (blue arrow) around it. Mild dilated congested portal vein (PV). Note: normal blood sinusoids(S) (**H&E X 400**).

F: Liver section of Vitamin C treated (**Group C**) showing a central vein (CV) surrounded normal hepatocytes. minimal inflammatory cells infiltration (black arrow) and vacuolation of cytoplasm (blue arrow). mild dilatation of blood sinusoids (S). (**H&E X 400**).

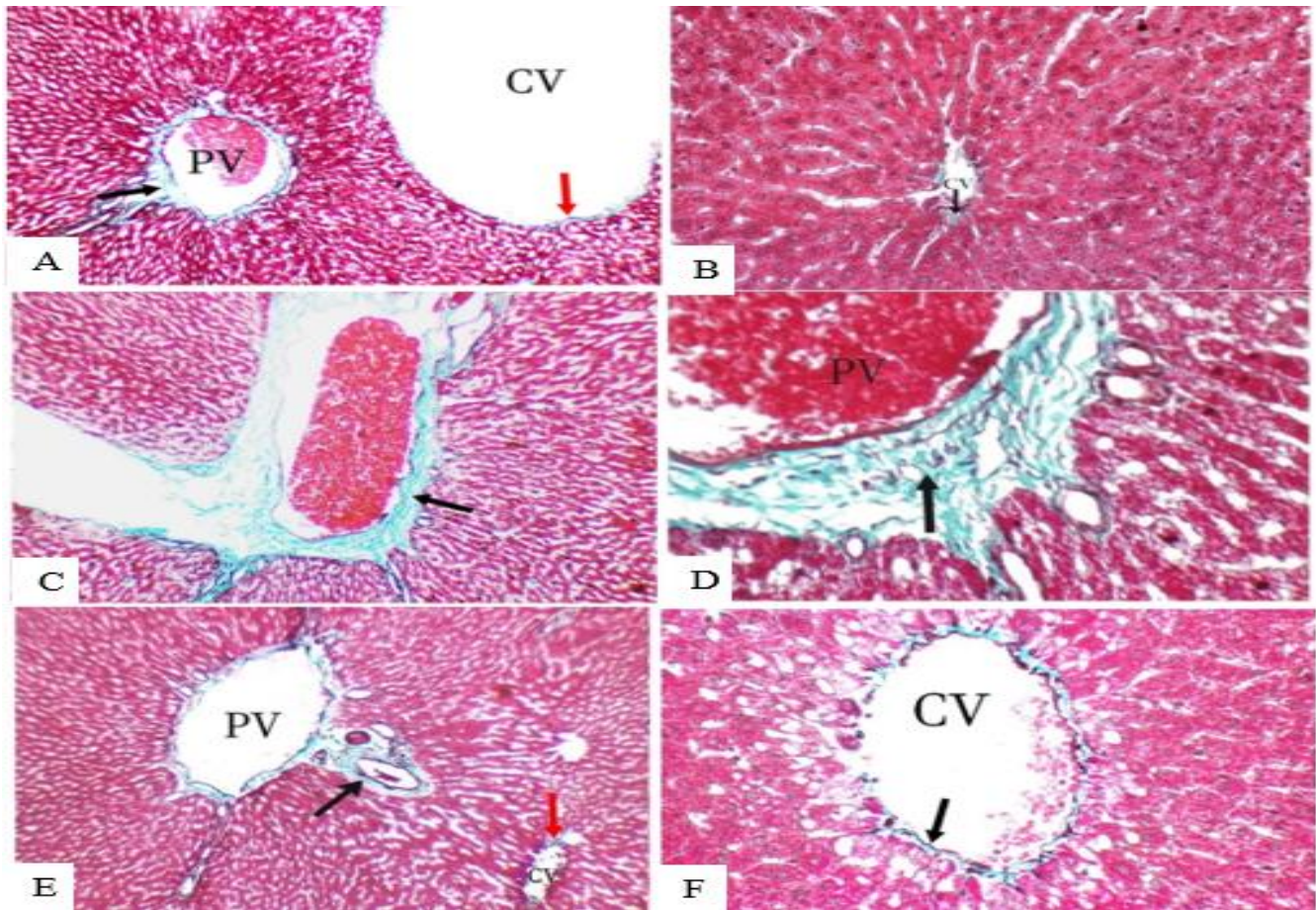


Figure 2. A photomicrograph of A: Liver section of a control (group A) showing minimal stromal collagen fibers distribution around central vein (CV) (red arrow) and portal tract (PT) (black arrow) (Masson trichrome X 200).

B: Liver section of the control (Group A) showing minimal stromal collagen fibers distribution around portal tracts (black arrow) (Masson trichrome X 400).

C: Liver section of AC treated (Group B) showing dense collagen fibers distribution around portal tract (PT) (black arrow). (Masson trichrome X 200).

D: Liver section of AC treated (Group B) showing dense collagen fibers distribution around portal tract (PT) (black arrow) (Masson trichrome X 400).

E: Liver section of Vitamin C treated (Group C) showing minimal collagen fibers distribution around the central vein (CV) (red arrow) and portal tract (PT) (black arrow) (Masson trichrome X 200).

F: Liver section of Vitamin C treated (Group C) showing negative cytoplasmic NF-kB p65 reactivity around portal tract (black arrow) and central vein (red arrow). (NF-kB immunostain X 400).

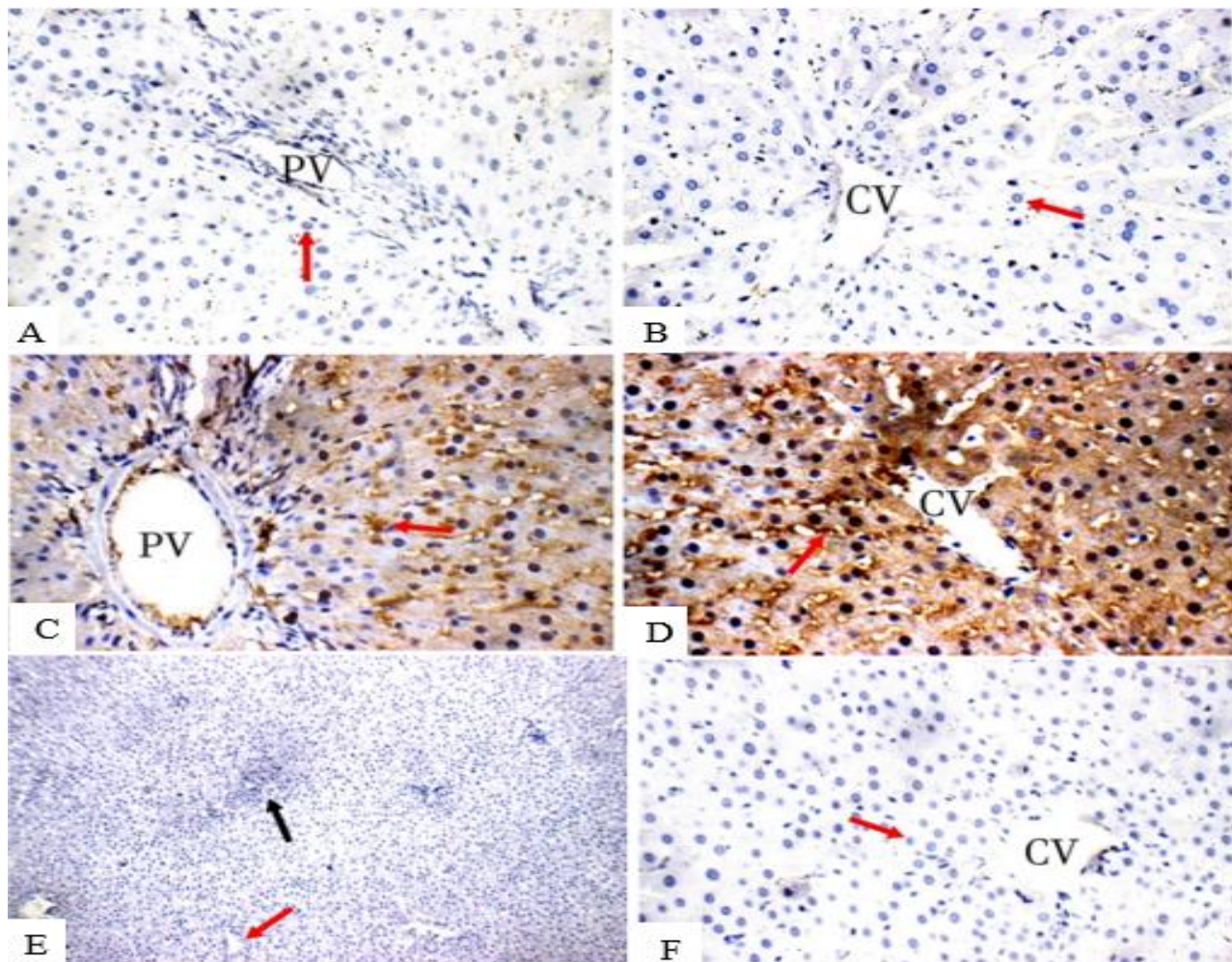


Figure 3. A photomicrograph of A: Liver section of a control (group A) showing negative cytoplasmic NF- κ B p65 reactivity in around portal tract (red arrow) (NF- κ B immunostain X 400).

B: Liver section of the control group (Group A) showing negative cytoplasmic NF- κ B p65 reactivity around central vein (red arrow) (NF- κ B immunostain X 400).

C: Liver section of AC treated (Group B) showing positive cytoplasmic NF- κ B p65 reactivity indicated by the presence of numerous dark brown stained hepatocytes around portal tract (red arrow) (NF- κ B immunostain X 400).

D: Liver section of AC treated (Group B) showing positive cytoplasmic NF- κ B p65 reactivity indicated by the presence of numerous dark brown stained hepatocytes around central vein (red arrow) (NF- κ B immunostain X 400).

E: Liver section of Vitamin C treated (Group C) showing negative cytoplasmic NF- κ B p65 reactivity around portal tract (black arrow) and central vein (red arrow). (NF- κ B immunostain X 400).

F: Liver section of Vitamin C treated (Group C) showing negative cytoplasmic NF- κ B p65 reactivity around central vein (red arrow) (NF- κ B immunostain X 400).

Table 1. Mean values of the liver function enzymes in the serum and the oxidant/antioxidant status markers in the liver tissue in the three groups

	Parameters	Group A	Group B	Group C
Liver Enzymes	AST (U/L)	15.37 ± 2.11	73.47 ± 4.59 ^a	19.65 ± 4.23 ^{bc}
	ALT (U/L)	14.92 ± 1.73	60.73 ± 9.85 ^a	17.15 ± 2.38 ^{bc}
	ALP (U/L)	131.23 ± 3.5	304.5 ± 28.44 ^a	143.49 ± 5.38 ^{bc}
	LDH (U/L)	79.78 ± 5.74	193.82 ± 21.69 ^a	86.43 ± 7.62 ^{bc}
oxidant/antioxidant markers	MDA (nmol/mg)	5.81 ± 1.63	43.45 ± 8.94 ^a	11.64 ± 6.31 ^{bc}
	GSH (nmol/mg)	61.45 ± 4.21	18.74 ± 7.34 ^a	55.24 ± 6.12 ^{bc}

* P value was calculated by Independent Sample T-Test.

* The data were represented in mean ± SD (Standard deviation)

a = Significant when compared to the same parameter in group A (P < 0.05)

b = Significant when compared to the same parameter in group B (P < 0.05).

c = non-significant when compared to the same parameter in group A (P > 0.05).

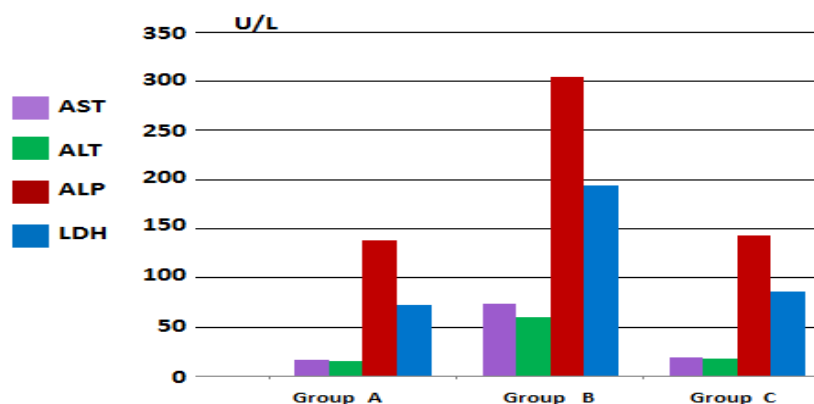


Figure 4: Mean level values of the liver function enzymes; aspartate transaminase (AST), alanine transaminase (ALT), alkaline phosphatase (ALP) and lactate dehydrogenase (LDH) in the serum.

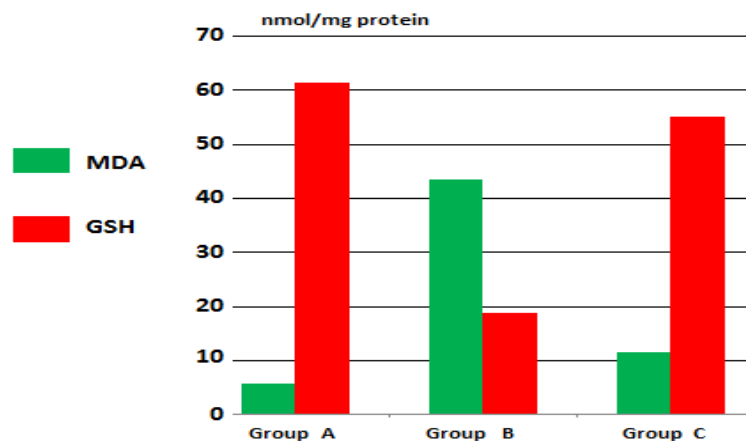


Figure 5 : Mean level values of the oxidant/antioxidant status markers; malondialdehyde (MDA) and Glutathione (GSH) in the liver tissue

Discussion

Amoxicillin-clavulanic acid is a hepatotoxin that causes mixed-pattern damage. Exposure to AC lead to liver tissue oxidative stress as well as hepatic injury.⁽³⁾

LM study of Group (II) (amoxicillin -clavulanic acid treated) by H&E showed distortion of the liver architecture surrounding portal tracts and central veins. Marked inflammatory cells infiltration and vacuolation around them. The blood sinusoids and portal veins were markedly dilated and congested.

The result of light microscope was confirmed by **Hussein et al**⁽¹²⁾ who attributed the observed distortion in the liver architecture including vacuolation, necrosis and inflammatory changes the cytotoxic action of AC on the liver, which interferes with the liver's regular role in detoxifying and other processes.

As a form of cellular defense mechanism against toxic substances, vacuolation in hepatocytes has been recognized as ballooning degeneration.⁽¹³⁾

Apoptosis and necrotic cell death have been associated with cellular degeneration.⁽¹⁴⁾ When amoxicillin/clavulanic acid induces apoptosis, it's accompanied by a rise in oxidative reactive molecules and a fall in antioxidants. According to researchers.⁽⁴⁾

Numerous pro-inflammatory cytokines associated with liver injury are the main cause of Augmentin-induced hepatotoxicity in rats.⁽¹⁵⁾

Cellular infiltration is a hallmark of ongoing inflammation. In response to particle matter and potent microbial antigens, macrophages become active.⁽¹⁶⁾

present study provided evidence of AC-induced hepatic fibrosis by collagen fiber deposition around portal tract and central vein. This agreed with⁽¹⁵⁾ who observed that administering AC to rats caused an area of hepatic necrosis and fibrosis.

Hepatocytes around the portal tract and central vein were positively stained in dark brown, indicating cytoplasmic NF-kB p65 reactivity.

Hepatotoxins like arsenic increase NF-kB immunoreactivity in hepatocyte cytoplasm, supporting a previous finding by **Miltonprabu and Muthumani** .⁽¹⁷⁾

NF-kappa B (NF-kB) is a transcription factor that helps regulate several cellular functions, including differentiation, proliferation, and survival, as well as innate and adaptive immunity and inflammatory responses.⁽¹⁸⁾ Increased proinflammatory cytokines and ROS stimulate NF-kB kinase pathways. AC-induced hepatotoxicity causes inflammatory alterations by transferring NF-KB to the hepatic cell nucleus, binding to DNA, and upregulating the transcription of several inflammatory genes like cytokine and chemokine.⁽¹⁹⁾

The AC-treated group had significantly elevated serum levels of the liver enzymes AST, ALT, ALP, and LDH and greater liver tissue MDA and lower GSH levels than the control group.

Hepatic membrane damage was shown by an increase in serum levels of biochemical indicators of liver injury following AC treatment The role of reactive oxygen species and lipid peroxidation in the development of AC-induced damage was established by **El-Kholy et al** .⁽²⁰⁾

As a result of lipid peroxidation and the inability of antioxidant defense systems to scavenge free radicals, there is a significant increase in blood MDA levels in the AC group compared to the control group, demonstrating the presence of liver injury. Similar results were found by^(21;22), demonstrating that AC therapy led to liver damage and lipid peroxidation.

The light microscopic analysis of the (vitamin C-supplemented group) (Group III) by H&E showed an improvement and restoration of the liver architecture as regular plates of hepatocytes around the central veins and portal tracts The blood sinusoids showed improvement, but there was mild dilatation in a few of them also mild dilatation in portal veins was seen

There were visible normal hepatocytes and others with mild vacuolation and inflammatory cell infiltration. The outcomes matched those of⁽²³⁾, who discovered that hepatocytes pretreated with vitamin C exhibited mild dilatation, congestion of sinusoids, and minimal vacuolation of cytoplasm, while histopathological degeneration in tissues from toxic agents was significantly reduced.

The inflammatory effects of AC are counteracted by VC's powerful anti-inflammatory component, which inhibits the production of inflammatory cytokines. Additionally, their effects on oxidant markers can reduce oxidative stress. ⁽¹²⁾

Collagen fibers between the hepatocyte cords were nearly identical to those found in the control groups, with a little distribution around the central vein and portal tract.

Studies indicate the positive effect of vitamin C intake in preventing both lipid peroxidation and type I collagen production. ⁽²⁴⁾

The peri-portal and peri-venular regions of the liver displayed negative cytoplasmic reactivity for NF- κ B p65. Vitamin C can also play an indirect antioxidant role by blocking (NF- κ B) activation, a process that aids in the generation of (ROS). ⁽²⁵⁾

Group III showed a significant blood liver enzyme remission, MDA reduction, and GSH increase compared to group II. When given AA and AC, group III's markers neared the control groups, showing that VC restored antioxidant capacity and improved lipid peroxidation. Vitamin C significantly reduced AC's hepatotoxicity. The significant remission of blood liver enzymes, MDA reduction, and GSH elevation in group C compared to group B showed that VC protects against AC-induced hepatotoxicity. Similar results were reported by. ⁽¹²⁾

Conclusion:

- The hepatotoxic, inflammatory, and oxidative effects of AC on liver tissue can be reduced by administering vitamin C, which is a powerful anti-inflammatory and antioxidant chemical that reduces hepatocyte degeneration and restores their cytoplasm.

References:

- 1- **Moore KL and DalleyAF:** Clinically oriented anatomy, Ch (5), Abdomen (Abdominal viscera),(8th) Ed, Wolters Kluwer India Pvt Ltd 2018; PP: 491-500.
- 2- **Ghabril M , Chalasani N and Bjornsson E.:** "Drug-induced liver injury: aclinical update". Curr. Opin.Gastroenterol., 2010; 26: 222-226.
- 3- **El-HosseinyLS, Alqurashy NN and Sheweita S. (2016):** Oxidative stress alleviation by sage essential oil in co-amoxiclav induced hepatotoxicity in rats: International journal of biomedical science. IJBS .2016; 12(2) - 71..
- 4- **Yu Z, Guo F , Zhang Z , Luo X , Tian J and Li H:** Protective Effects of Glycyrrhizin on LPS and Amoxicillin/Potassium Clavulanate-Induced Liver Injury in Chicken: Pakistan veterinary journal.2017;37(1).
- 5- **Stine JG and Chalasani N:** "Chronic liver injury induced by drugs: a systematic review". Liver Int. 2015; 35 (11): 2343-2353.
- 6- **Jacob R A and Sotoudeh G.:** Vitamin C function and status in chronic disease. Nutrition in clinical care.2012; 5(2): 66-74..
- 7- **Seghrouchni, I, Draï J, E. Bannier, E J. et al:** "Oxidative stress parameters in type 1, type 2 and insulin-retreated type 2 diabetes mellitus: Insulin treatment efficiency". Clin. Chim.Acta.2012; 321 (1-2): 89-96..
- 8- **Ergul Y, Erkan T, Uzun H, Genc H, Altug T and Erginoz :** E. Effect of vitamin C on oxidative liver injury due to isoniazid in rats: Pediatrics International .2010; 52(1): 69-74.
- 9- **Lowes DA, Galley HF, Moura AP, Webster NR:**Brief isoflurane anaesthesia affects differential gene expression, gene ontology and gene networks in rat brain. Behav Brain Res.2017; 317: 453-60.
- 10- **Sharma A, Fish BL, Moulder JE, Medhora M, Baker JE, Mader M and cohenEP:**Safety and blood sample volume and quality of a refined retro orbital bleeding technique in rats using a lateral approach. Lab Anim. 2014; 43: 63-66.
- 11- **Chen L, Li S, Guo X, Xie P, Chen J:**The role of GSH in microcystin-induced apoptosis in rat liver. Involvement of oxidative stress and NF κ B. Environ toxicol .2016; 31 (5): 552-60.
- 12- **Hussein A ,Elwia S , Abd El Rahman S and Fakhem H:** Modulatory Role of Gallic Acid and Vitamin C on Amoxicillin/Clavulanic Acid Combination Induced Hepatotoxicity in Adult Albino Rats. Mansoura Journal of Forensic Medicine and Clinical Toxicology.2020;28(1): 55-71.

- 13- **Abdel Hameed TF:** Light and electron microscopic studies on the effect of orally administered formalin on liver and kidney of guinea pig, *Journal of the Egyptian German Society of Zoology C. Histology and Histochemistry*.2014; 45 (c): 203-224.
- 14- **Brauchile E, Thude S. Brucker SY. and Lay-Land K.:** Cell death stages in single apoptotic and necrotic cells monitored by Raman microspectroscopy *Sci. Rep.*, 4: 4698. Published online 2014 Apr., 15. doi:10.1038/srep04698.
- 15- **El Shemy MA:** Protective effects of curcumin against Augmentin-induced hepatotoxicity in rats. *Benha Vet. Med. J.*2019; 35(1), 375-86.
- 16- **Cheville NF:** Ultrastructural pathology: The comparative cellular basis of disease. 2nd ed. Wiley-Blackwell. A John Wiley of Sons. Inc. USA., 2009.
- 17- **Miltonprabu S and Muthumani M:**Dimethoxycurcumin potentially protects arsenic induced oxidative hepatic injury, inflammation and apoptosis via Nrf2-Keap1 signaling in rats. *Biomedicine and Preventive Nutrition*.2014;4(4), 561-577.
- 18- **Liu T, Zhang L, Joo D, Sun SC:**NF-kappaB signaling in inflammation. *Signal Transduct. Target* .2017; 2, 17023.
- 19- **Igor OM, Fabiane F, Camila RC and Giuseppina L:** Antioxidant Activity of γ -Oryzanol: A Complex Network of Interactions. *Inter J of Mol Sc.*2016; 17 (8): 1107.
- 20- **El-KholyWM, Hemieda FA and Elabani GM:**Role of Cinnamon Extract in the Protection against Amoxicillin/Clavulanate-Induced Liver Damage in Rats.2019.
- 21- **El-SherbinyGA, Taya A and Abdel-Raheem IA:**"Role of ursodeoxycholic acid in prevention of hepatotoxicity caused by amoxicillin-clavulanic acid in rats." *Annals of Hepatology* ".2009; 8 (2):143-40.
- 22- **Delemos AS, Ghabril M, Rockey DC, Gu J, Barnhart HX, Fontana RJ, Kleiner DE and Bonkovsky HL:** "Amoxicillin-Clavulanate-Induced liver injury." *Dig Dis Sci.*2016; 61 (8):2406-2416.
- 23- **Dosuky MA, Zaghlool DA, Ouies SM, Abdel-NaeimHA:** Effects of monosodium glutamate on the liver of male adult albino rat and the possible protective role of vitamin c (light and electron microscopic study). *The Medical Journal of Cairo University*.2018; 86(December), 3407-3418.
- 24- **Soylu AR, AydogduN ,Basaran UN , Altaner S, Tarcin O, Gedik N, Umit H, Tezel A , Dokmeci G , Baloglu H , Ture M , Kutlu K and Kaymak K :**Antioxidants vitamin E and C attenuate hepatic fibrosis in biliary-obstructed rats. *World J. Gastroenterol.*2006;12 (42): 6835–6841
- 25- **Moore A and Khanna D :**The Role of Vitamin C in Human Immunity and Its Treatment Potential Against COVID-19: A Review Article. *Cureus* .2023; 15(1).