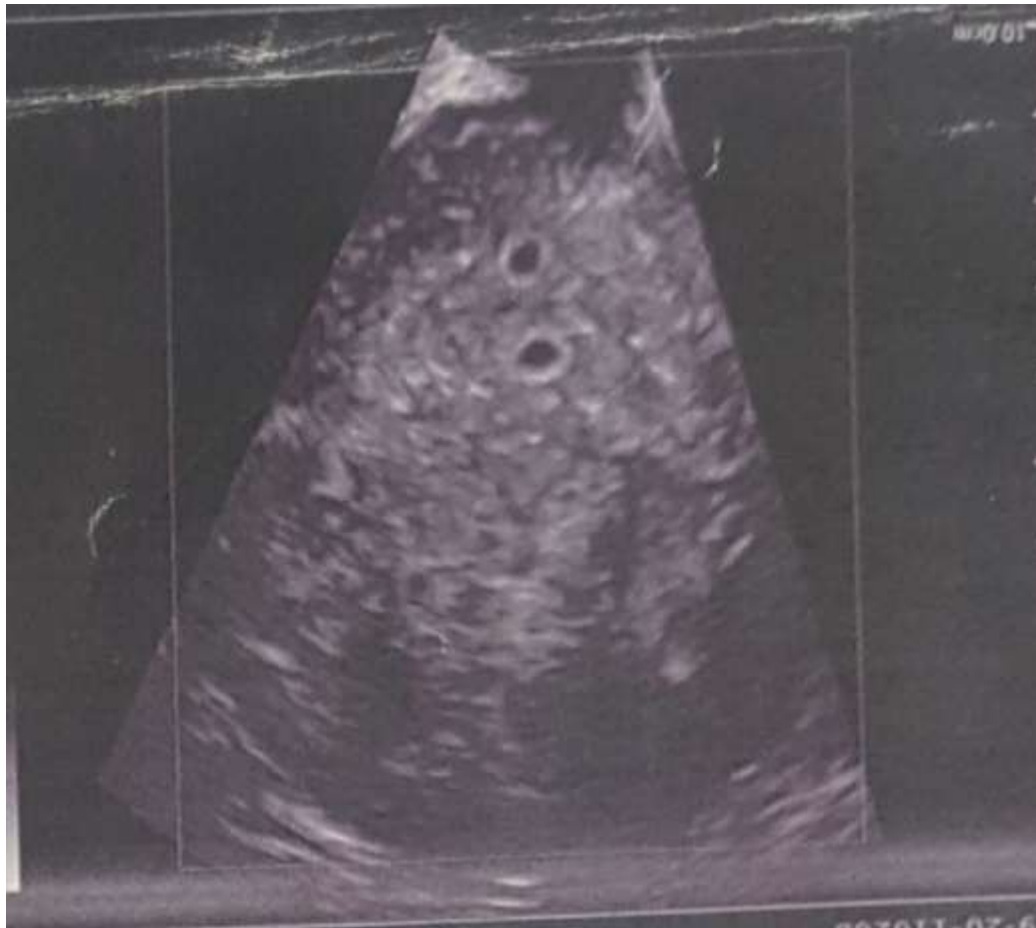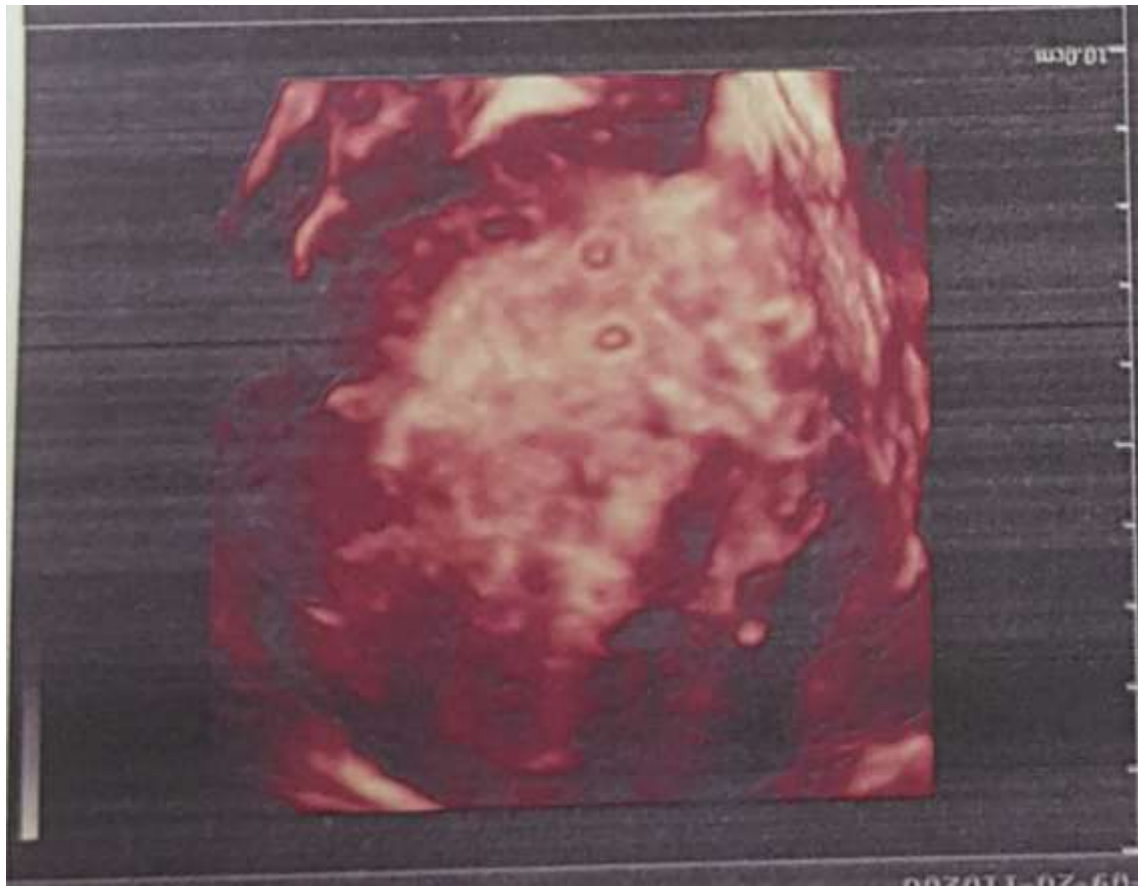

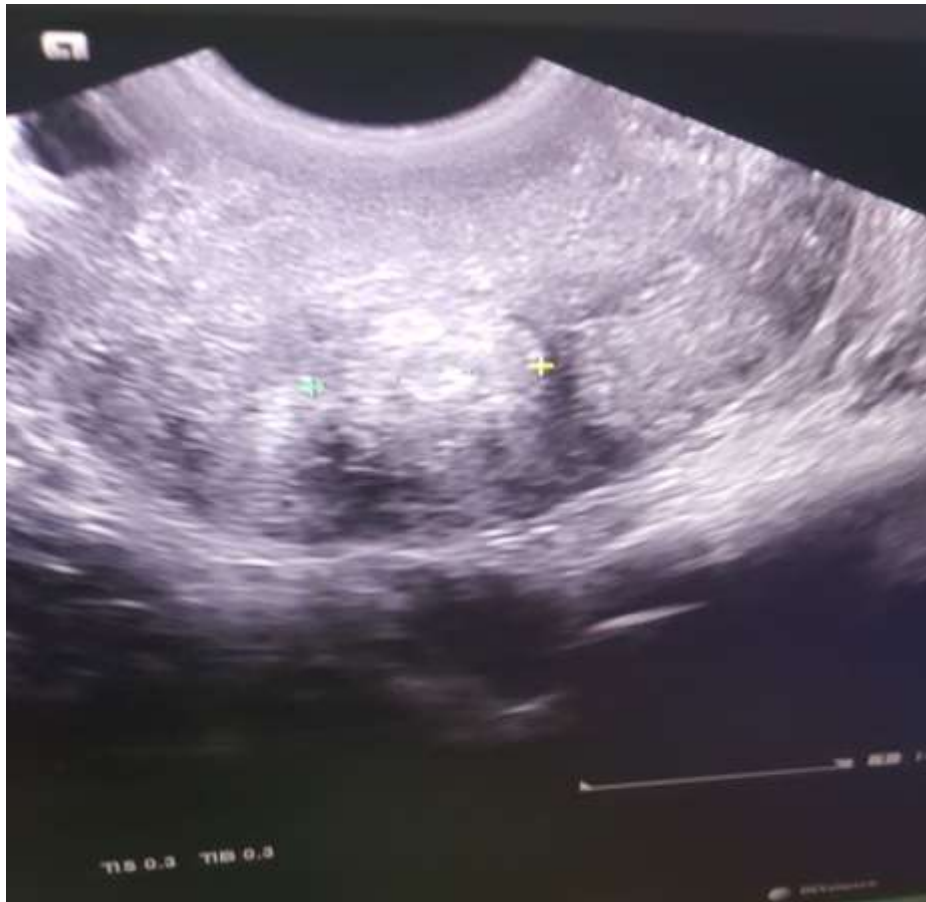


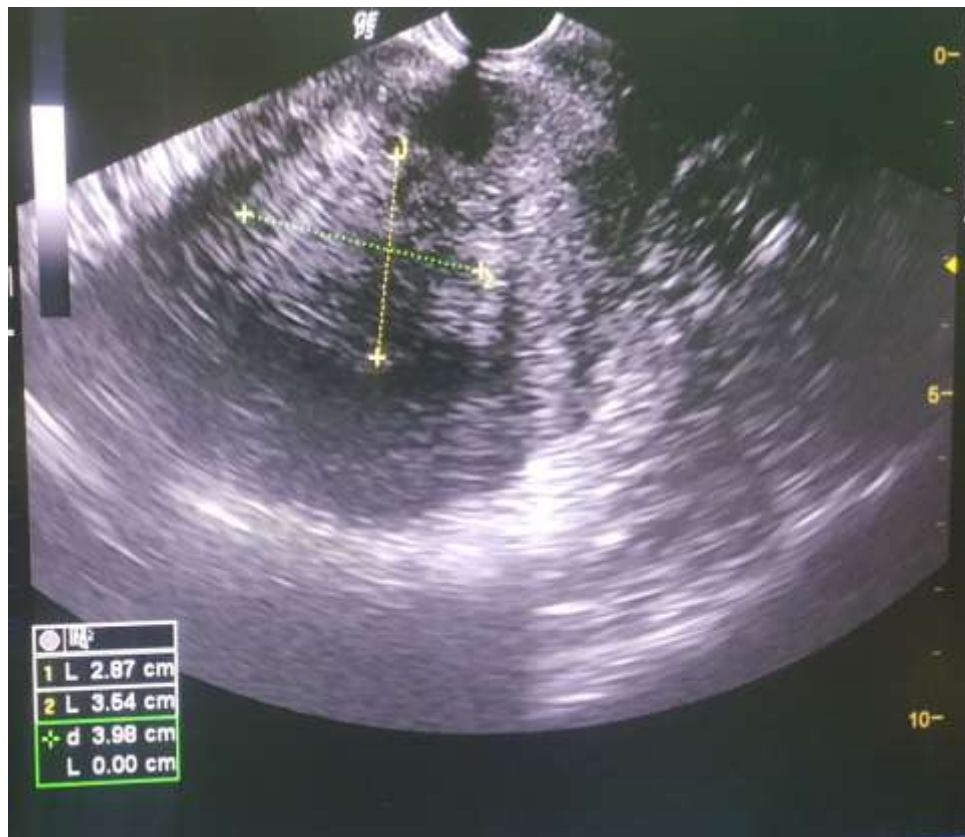
Pre-RFA 2D TVS



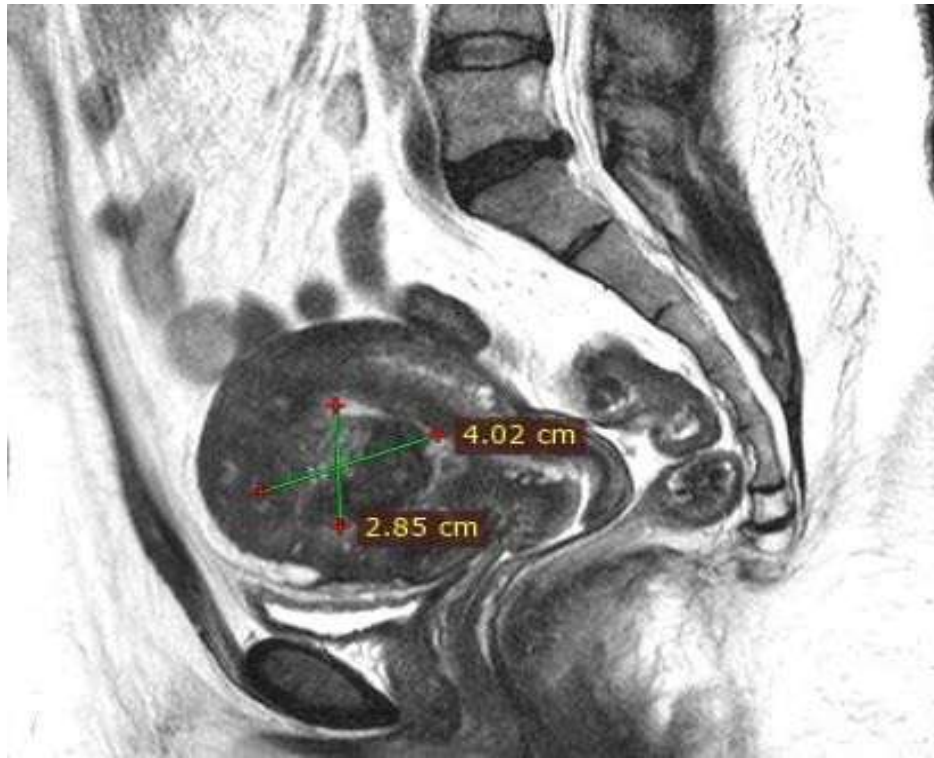Pre-RFA 3D TVS



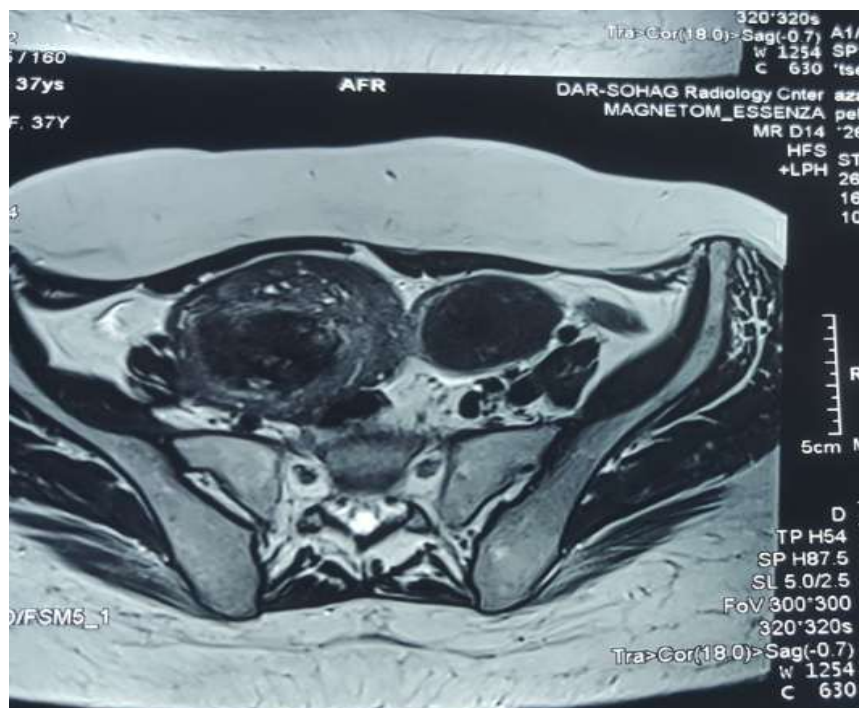
Post\_RFA 3 M.



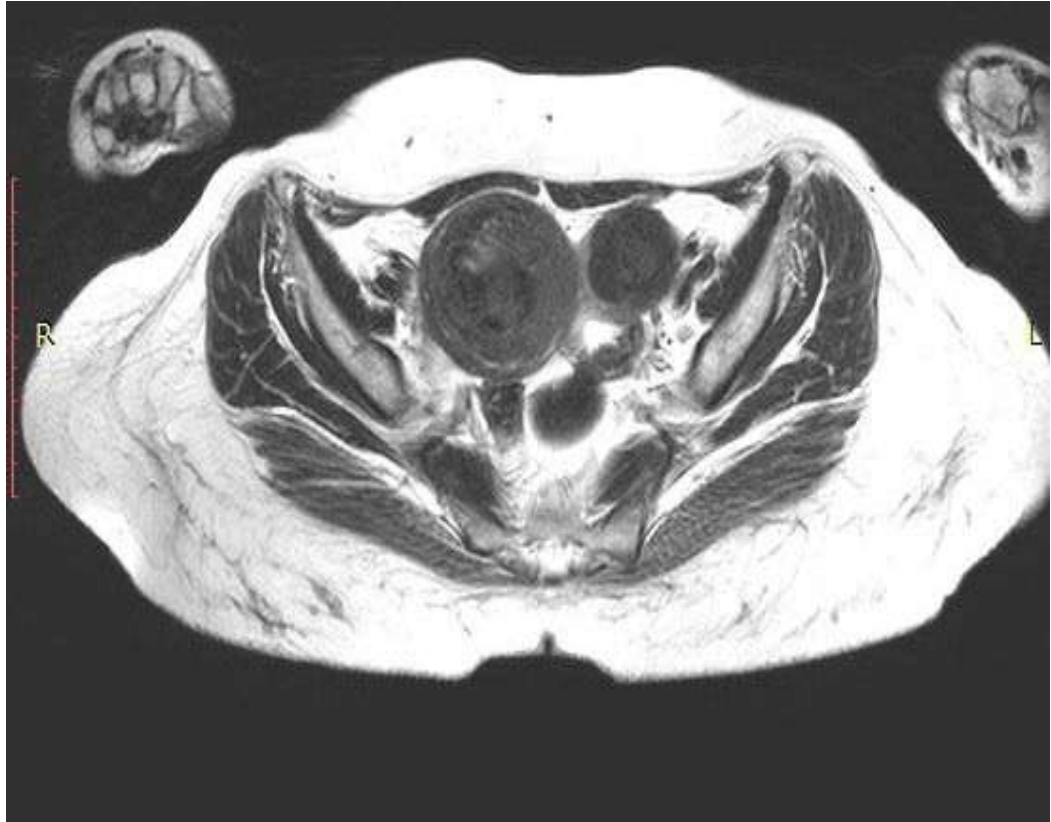
Post\_RFA 6 M.



MRI pelvis showing ant. Wall localized adenomyosis

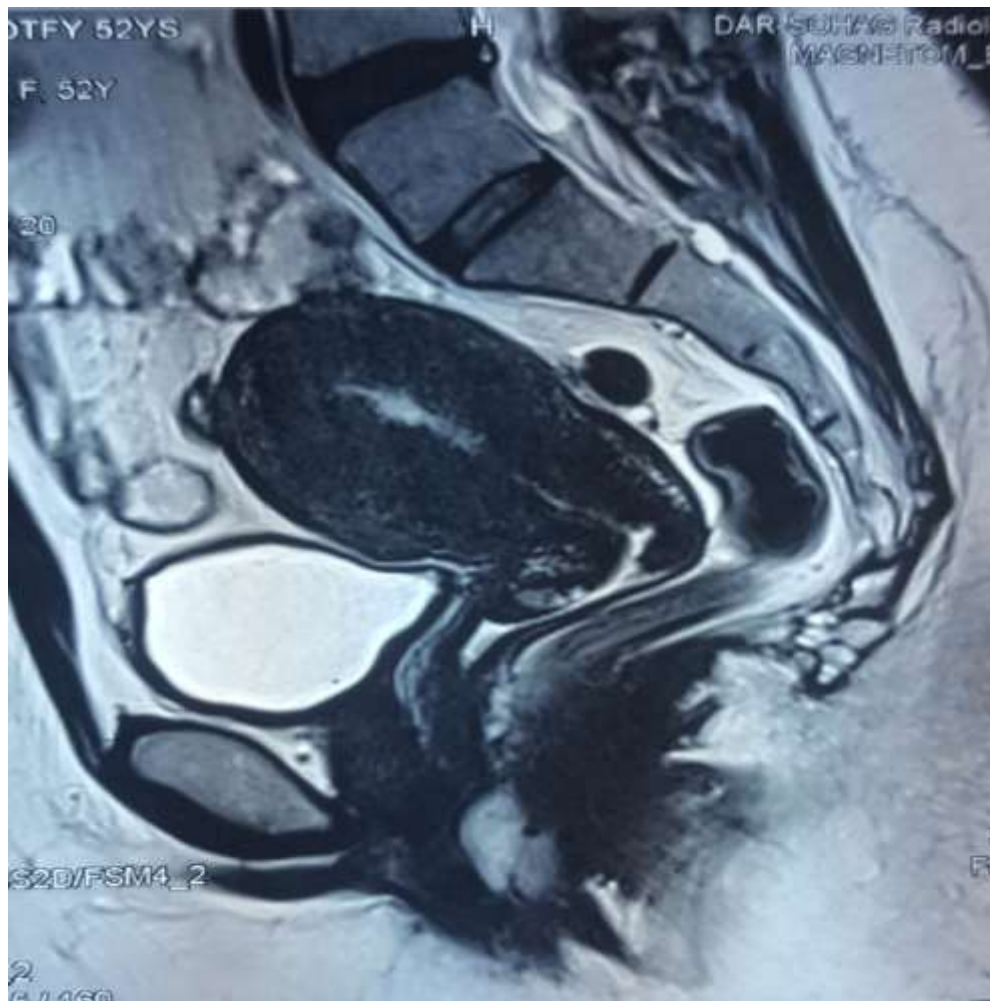


Pre-RFA MRI



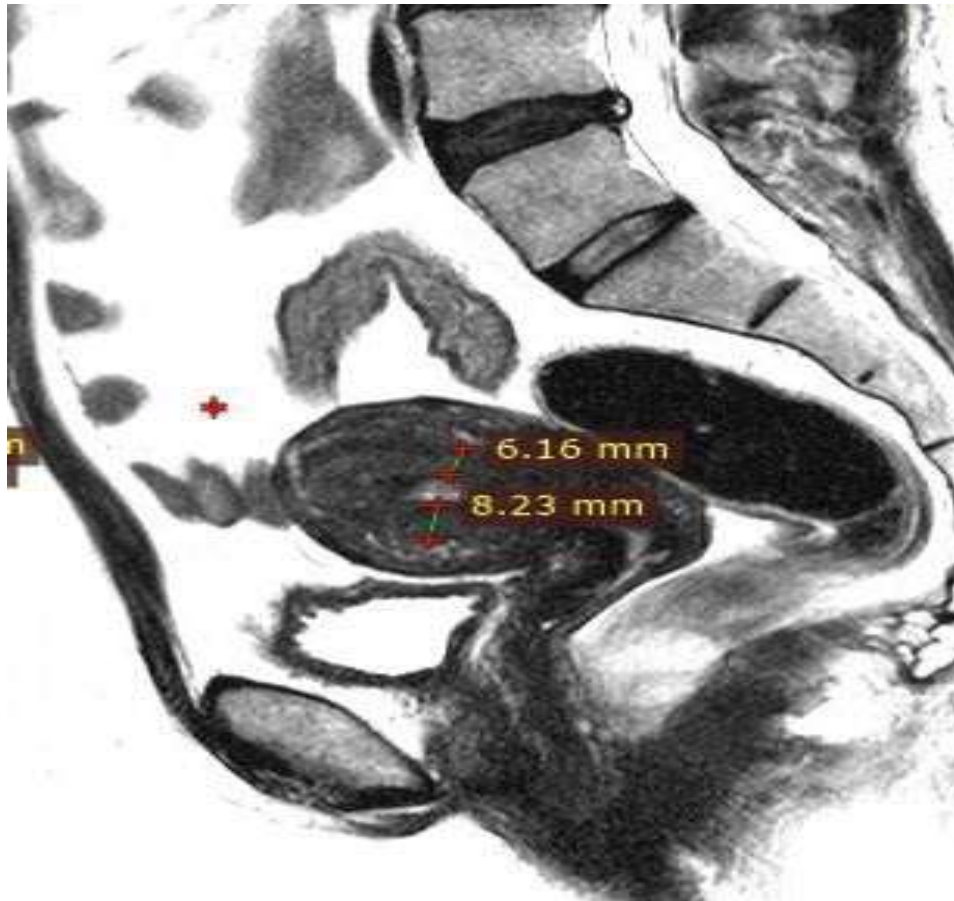
Post-RFA MRI





Pre-RFA MRI





Post-RFA MRI

