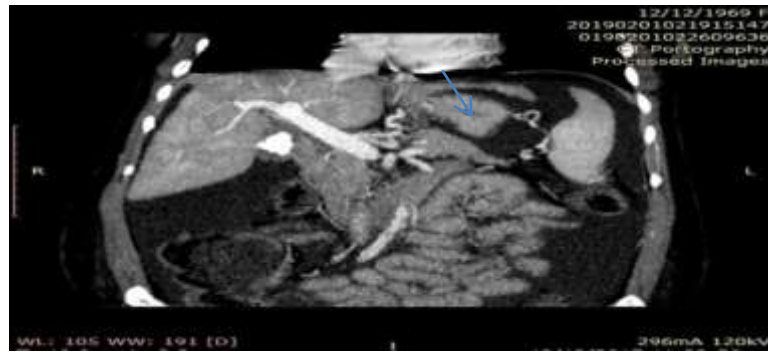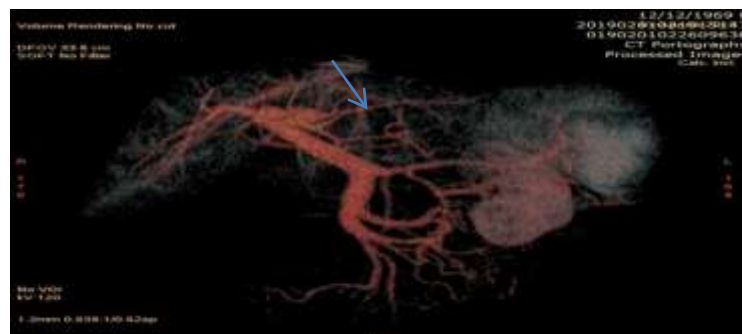


(A)



(B)

Female patient 50 years old with a history of chronic liver disease complains of marked abdominal distension and lower limb edema.

The endoscopic findings: enlarged tortuous esophageal varices grade II

The MDCT findings: cirrhotic liver with ascites, dilated portal vein and porta hepatic collaterals grade III. (A) Triphasic CT (portal) coronal reconstruction image showing dilated porta hepatic collaterals (the blue arrow). (B) CT with 3D reconstruction showing dilated porta hepatic collaterals (the blue arrow)