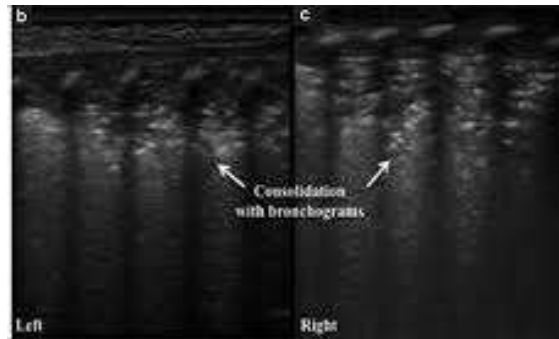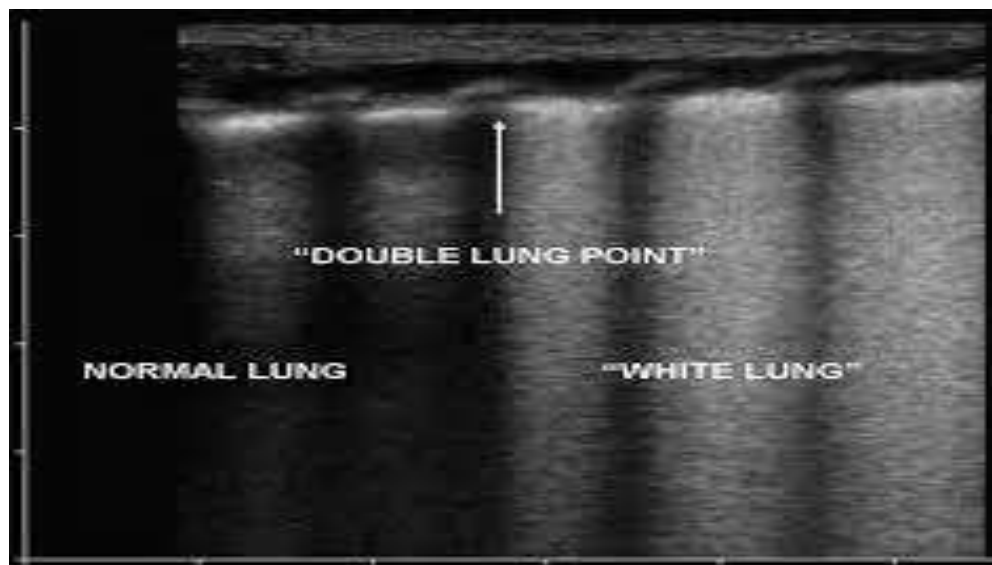


*Figure (1)lung consolidation in lung ultrasound*



*Figure (2) double lung point*