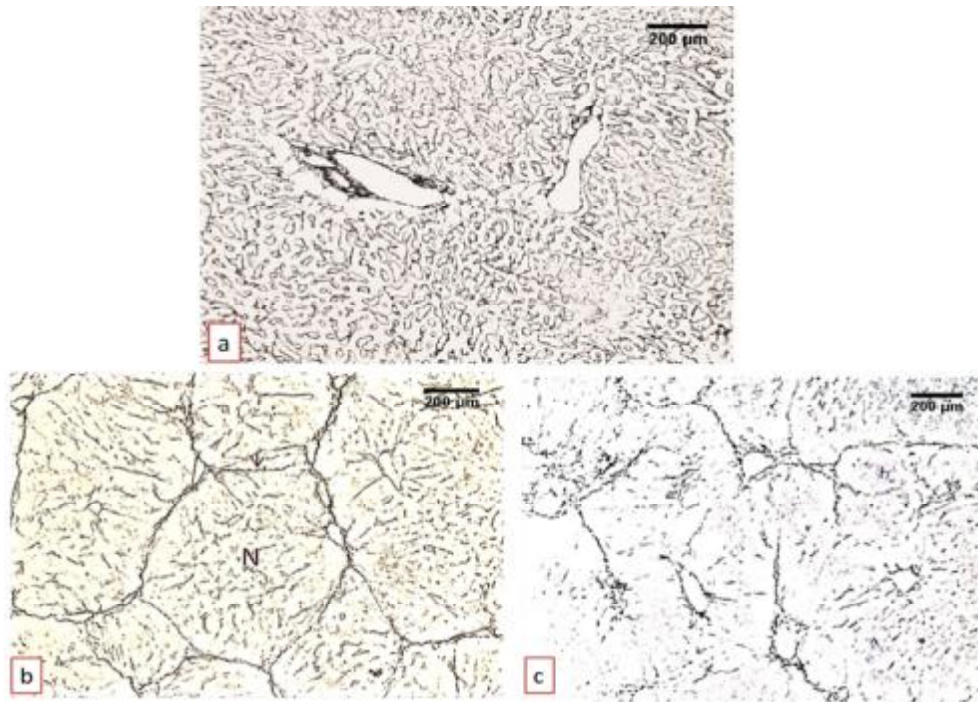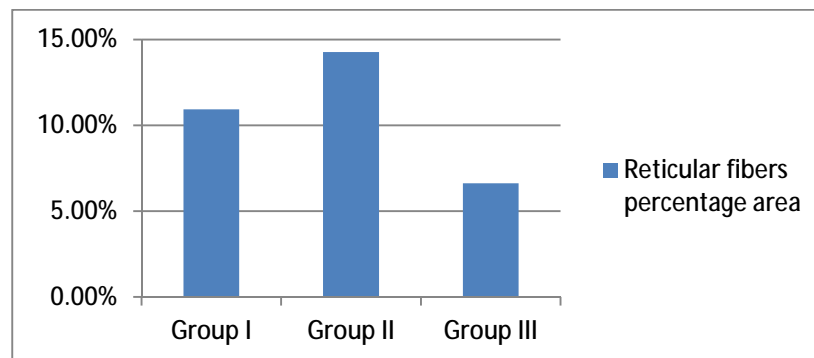


**Fig. (1):** Photomicrographs of liver sections from animals of; (a) group I showing reticular framework surrounding the central vein, in the portal area and around hepatic plates of hepatocytes.(b)group II showing numerous reticular fibers with complete septa surrounds the hepatic lobules and the cirrhotic nodules(N) and collapse of the fine fibers inbetween the parenchymal cells.(c) groupIII showing few reticular fibers around the central veins and in the portal areas with incomplete septae and inbetween the parenchymal cells (Silver stain).



**Fig.( 2):** The mean percentage area of reticular fibers.