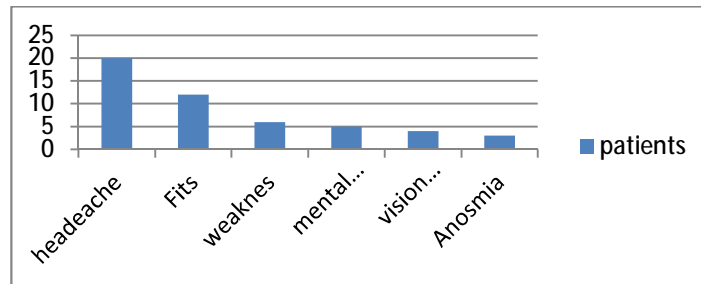
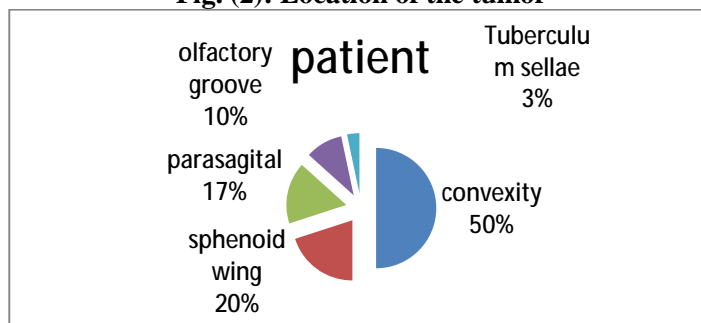


Fig. (1):Complaints



The lesion was related to the convexity in 14 cases, and to the sphenoid wing in 6 cases, and to the superior sagittal sinus in 5 cases.

Fig. (2): Location of the tumor



The lesion was totally removed in 24 cases and subtotal in 6 cases.

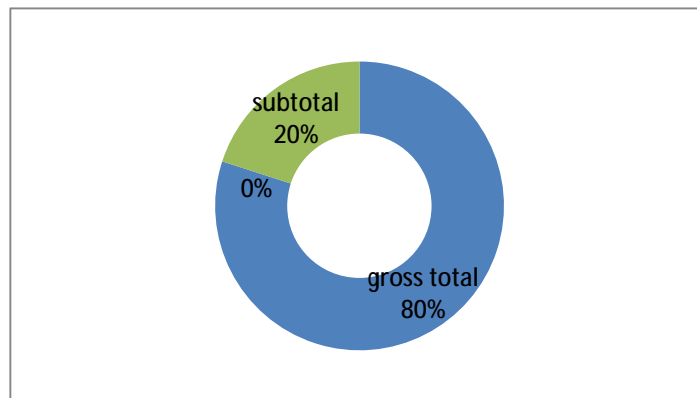


Fig. (3):Radicality

As for the pathology 7 cases with transitional meningiomas, 4 cases fibroblastic meningiomas, 2 cases with atypical meningiomas, 9 cases meningiothelial meningiomas, 5 cases psammomatus meningiomas, 3 cases mixed meningiomas

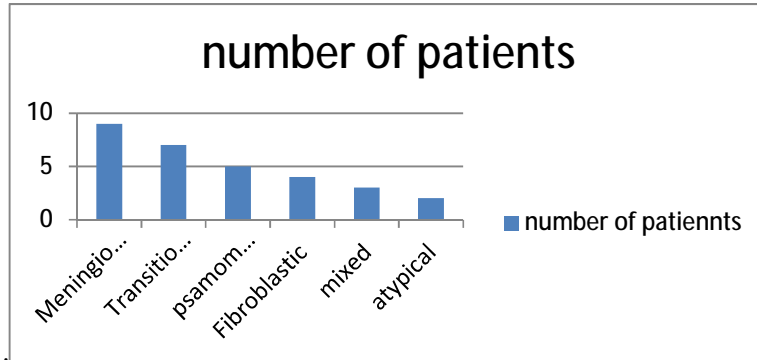


Fig. (4): Pathological types

Among the 30 patients 2 patient complicated by CSF leak and 4 patients complicated by wound infection, one patient developed hemorrhage and two patient show increased in weakness.

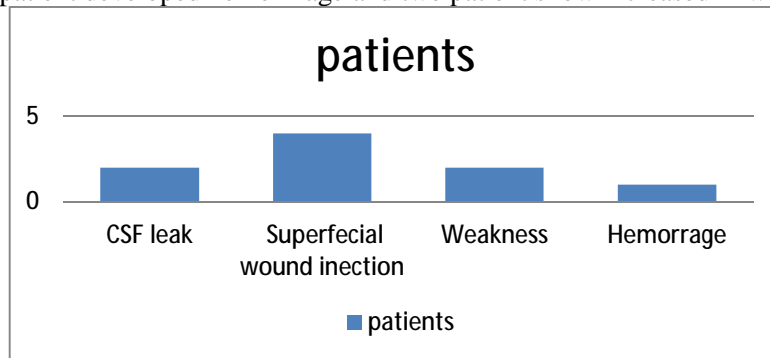


Fig (5):Complications

Among these 30 patients 22 patients improved, 7 patients remained the same and 1 patient deteriorated.

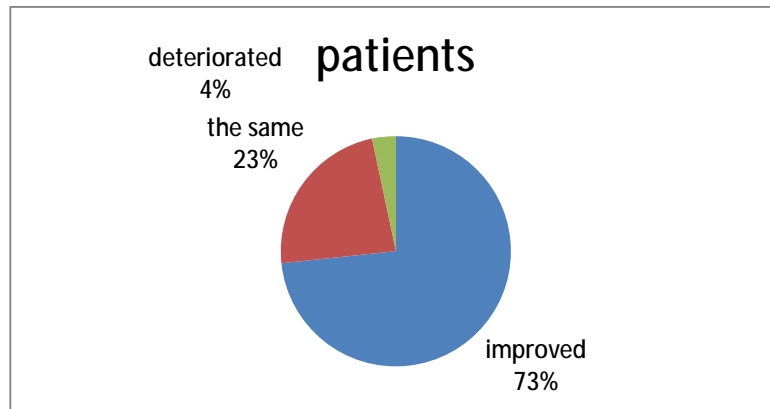


Fig. (6):Outcome