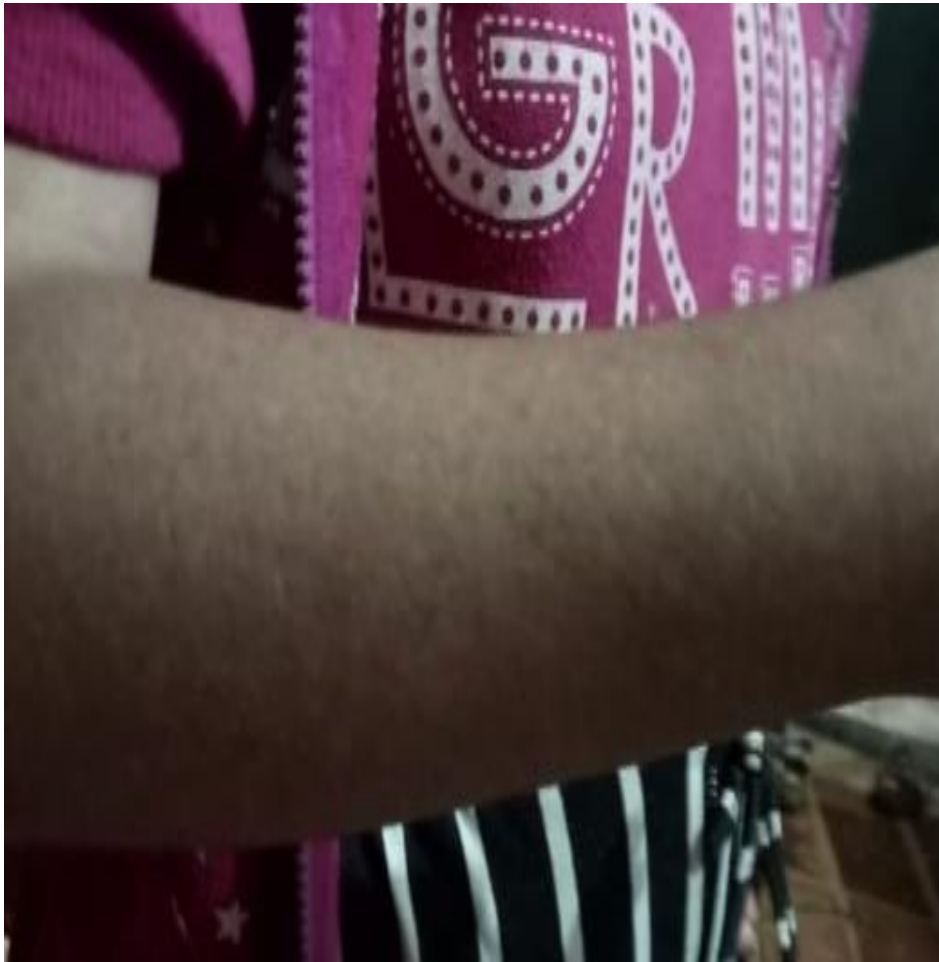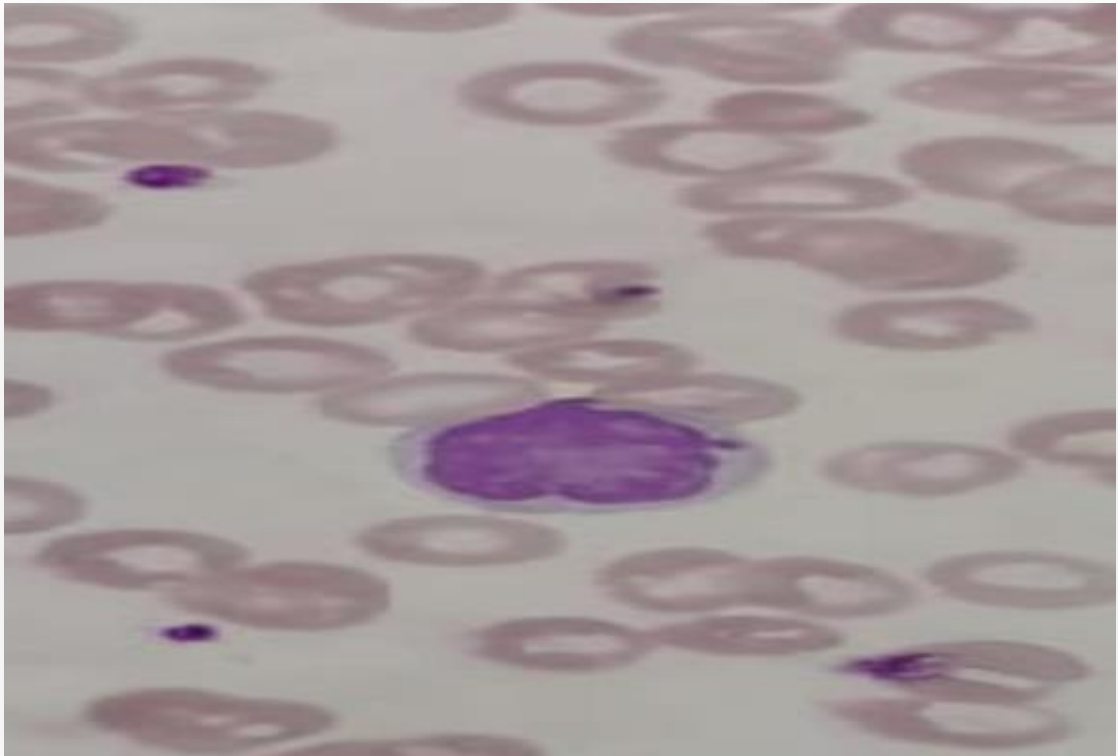

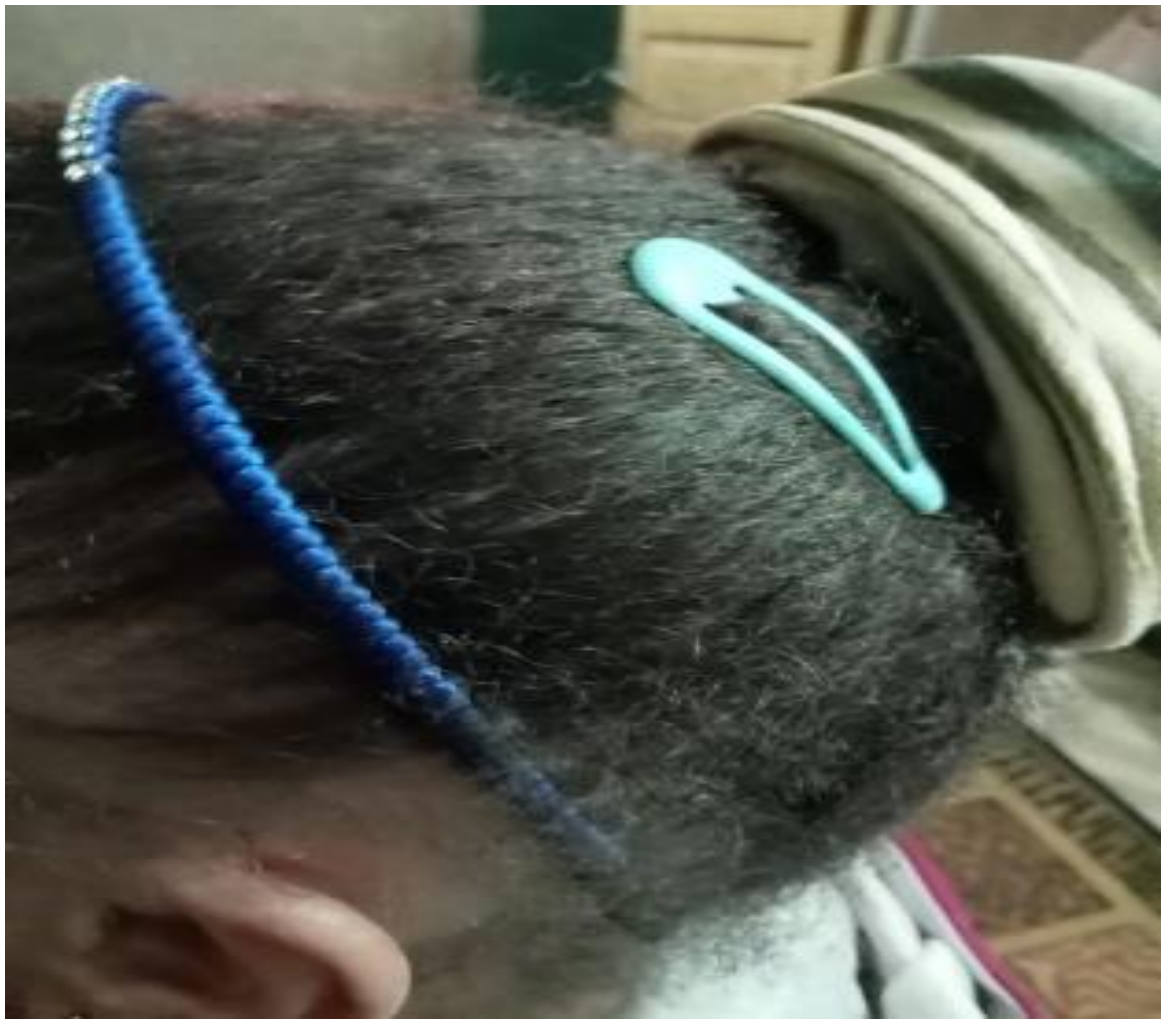


**Figure (1): -Shows hypopigment-ation in the arm.**



**Figure (2):** - Peripheral blood film showing abnormal giant intracyt-o-plasmic granules in WBC with ab-normal forms consistent with CHS, complicated by HLH



**Figure (3)** shows silver, grey hair.