



Drawbacks of conservative treatment of proximal humerus fractures in elderly

Tharwat Bahgat , Mohamed Abd Wanis, Moustafa Elsayed

*Department faculty of medicine Sohag University Egypt

Abstract

Background Fractures of proximal humerus are popular in older people. About $\frac{3}{4}$ of proximal humerus fractures occur in patients older than sixty. Several methods of internal fixation and arthroplasty are used. However conservative treatment continues to be used in this age group, although some complications of conservative management limit its indications.

Objective To assess the outcomes of conservative treatment of proximal humerus fractures in elderly patients.

Methods It is a retrospective study of 30 elderly patients (over 50 ys) who suffered from proximal humerus fractures and received conservative treatment using broad arm sling. All patients were subjected to regular clinical and radiological examination to evaluate the time of union, range of motion, residual pain and complications.

Results The average follow up time was 6 months. Nine cases (30%) showed nonunion while 11 cases (37%) showed delayed union after 3 months. The results showed 8 cases (27%) with a poor range of motion and 13 cases (43%) with an acceptable range of motion while 9 cases (30%) showed a good range of motion. As regards Pain evaluation, 8 cases (27%) with moderate pain while 13 cases (43%) with mild pain and 9 cases (30%) showed no pain. There were 4 cases (13%) of malunion, 3 cases (10%) of avascular necrosis of humeral head, 4 cases (13%) of inferior subluxation of the humeral head and 2 cases (7%) of posttraumatic arthritis.

Conclusion Conservative treatment of proximal humerus fractures in elderly patients is associated with a significant incidence of unsatisfactory outcomes and should be limited only to patients unfit for surgery.

Keywords: Proximal Humerus Fractures, Elderly, Conservative Treatment

Introduction:

Fractures of proximal humerus are common in older people. It may end in a vital malfunction for the patient. Data on the composite anatomy of the shoulder is overriding in the proper treatment of those fractures. Fractures of the proximal humerus attribute for five percent of all fractures, and that they are third in prevalence among the foremost familiar forms of fractures. (1, 2) The bulk of those fractures are low energy fractures occurring in older patients.

(3) Frequency tends to increase with age. Females over the age of sixty with a history of osteoporosis are more commonly affected. (2, 4, 5) Nearly $\frac{3}{4}$ of proximal humerus fractures occur in patients older than sixty who have fallen on extended hand. (2, 3)

Risk factors for proximal humeral fractures embrace older patients, osteoporosis, no history of endocrine replacement medical aid and smoking. (2,3,6) No matter the age of the patient or

mode of trauma, a recreation of the painless purposeful amplitude of movement remains the first treatment aim of those fractures. (2)

There presently exists many dilemmas like once to perform surgery and that surgery is the most applicable methodology of treatment that has nonetheless to be definitively determined. High-level outcome-based mostly studies are presently being performed to assist answer queries. However, uncertainty still remains. (7) Regardless of treatment selected, early active mobilization has a junction rectifier to improve outcomes. Completely different internal fixation strategies are used as plates and screws, PHILOS, Intramedullary nailing, and K-wires. Arthroplasty may be a treatment choice in Comminuted fractures thanks to a high incidence of avascular necrosis. (2, 8)

Conservative treatment continues to be used for an outsized variety of proximal humeral fractures. (8, 9)

The indications for conservative management are stable nondisplaced or minimally displaced fractures, patients did not fit surgery and older patients with low purposeful demand. (9) The aim of this study is to judge the results of conservative treatment of those fractures in older individuals.

Patients and methods:

It is a retrospective study of thirty patients with proximal humeral fractures admitted in the orthopedic department of Sohag university hospital from Sep 2016 to June 2018. Inclusion criteria included: patients over 50ys old, non-displaced or minimally displaced fractures and displaced fractures in surgically unfit and low demand patients. Patients with open fractures, fracture-dislocation, associated fractures or previous fracture on the same side were excluded. An informed penned consent was obtained from all participants. The research was approved by Scien-

tific and Ethical Committee of Sohag faculty of medicine. All patients were treated conservatively using broad arm sling.

Immobilization was counseled for 2-3 weeks, followed by a gentle range of motion exercises. Resistance exercises were begun at 6 weeks. Isometric exercises to take care of strength during the first 6 weeks.

The patients were followed up radiologically using X-ray after one week, 3 weeks, 6 weeks, 3 months and 6 months and clinically at 6 weeks, 3 months and 6 months to judge the range of motion and presence of pain. The range of internal rotation, external rotation, abduction in the coronal plane, flexion, and extension was recorded. The result was considered acceptable if the patient could abduct above 60°. With the abduction of less than 60° or inability to reach above the head or behind the neck or any degree of pain, the result was considered poor. Abduction above 110° was classified as an honest result. As regarding pain, pain was classified as mild if it did not interrupt sleep or daily activities and did not need analgesics; it was considered moderate if it interfered with sleep or daily activities unless simple analgesics were given; and it was considered severe if it interfered with sleep or daily activities unless strong analgesics were given.

Results:

The study included thirty patients (13men). The average age was 67.9ys (51-89ys). The right shoulder was affected in sixteen patients while the left side was affected in fourteen patients. The average follows up was six months (5-7.5ms). According to Neer classification, fourteen cases (46.6%) were 2 part fractures, twelve cases (40%) were 3 part fracture and four cases (13.3%) are 4 part fractures. According to AO/OTA classification,

five cases (16.7%) typed A fracture, fifteen cases (50%) were type B fracture and ten cases (33.3%) were type C fracture.

At last, follow up:

Nine cases (33%) showed nonunion(Fig 1) after 6 months while eleven cases (37%) show delayed union after 3 months.

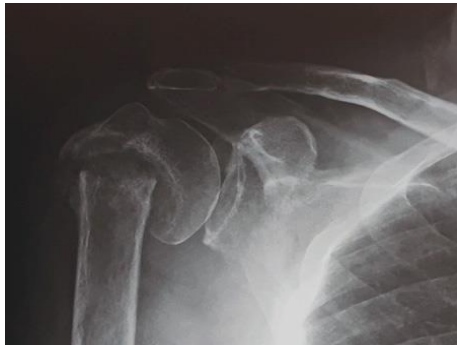

Fig 1. Nonunion case at 6 months follow-up with resorption of the surgical neck.

Evaluation of ROM showed eight cases (27%) with a poor range of motion and thirteen cases (43%) with the acceptable range of motion while nine cases (30%) showed a good range of motion. Pain analysis disclosed eight cases (27%) suffered from moderate pain while thirteen cases (43%) showed mild pain and nine cases (30%) had no pain. As regard presence of other complications (**Fig 2**), there were four cases (13%) of malunion (**Fig 3**), three cases (10%) of avascular necrosis of humeral head, four cases (13%) of inferior subluxation of the humeral head(**Fig 4**) and two cases(7%) of posttraumatic arthritis.

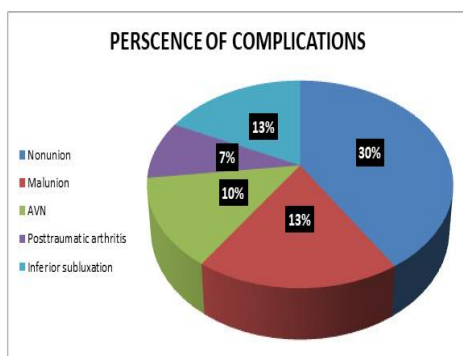


Fig 2.Percent of complications.

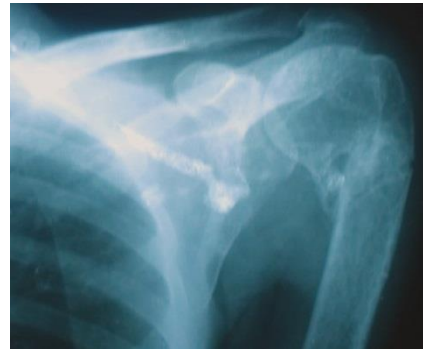

Fig 3.Malunioncase after 5 months follow up.

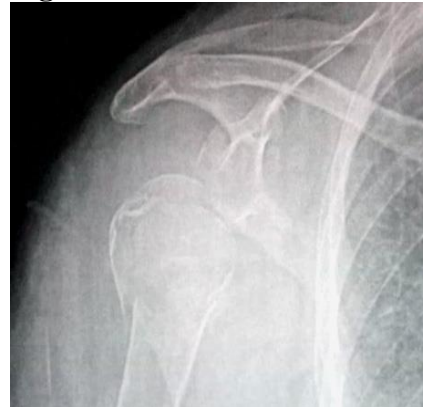

Fig4.Inferior subluxation of the humeral head.

Discussion:

Fractures of proximal humerus are common in the older population. This age group principally has other comorbidities. Conservative treatment is a safe option in this age group. But it is presented by some pitfalls of complications. That's why many studies were done to envision the result of conservative treatment in this age group. (3,7,10,11)

Court-Brown et al. (3) studied 131 two-part surgical neck fractures in patients with a mean age of seventy-three years for females and sixty-nine for males. conservative treatment yielded results just like those of surgical treatment even in fractures with translation sixty-six percent or additional.

Hanson et al. (10) evaluated the outcomes of non-operative treatment in seventy-five one-part, sixty two-part, twenty-three three-part fractures, and two four-part or head-splitting fractures. Four patients needed surgery due to displacement and five required arthroscopic-subacromial

decompression because of impingement. At one year after the fracture, the injured shoulders averaged an 8.2 point loss of Constant score. The highest variability in outcomes was found in patients with two-part fractures. Conservative treatment of comminuted four-part fractures has a poor outcome results. Despite poor constant scores, patient satisfaction levels remained good at 10-year follow-up.

During a prospective cohort study, Caceres et al. (11) examined non-operative management in each displaced and non-displaced proximal humerus fractures. Whereas healing occurred in most patients, constant scores worsened with worsening severity of the fracture. Practical outcomes improved increasingly from four-part to three parts and subsequently two-part fractures. Pain outcomes worsened with three and four-part fractures in relevance two-part injuries, and individuals who were under the age of 75 and had non-displaced injuries had improved practical outcomes.

In our study, although we had a short follow up time, but we tend to believe that these fractures heal well and expected to reach their final state by that time. The results point towards favorability of operative treatment. The shoulder is a highly mobile joint which is difficult to fix with arm sling, body bandage or other known methods of conservative treatment. Lack of fixation will definitely affect healing and outcomes. Even the mentioned previous studies could not solve the controversy and some of their patients required operative intervention after time.

New regional anesthesia techniques as brachial plexus block and scalene block with minimally invasive methods of fixation like percutaneous pinning can solve the problem of unfit patients and consequently the conservative treatment is reserved for non displaced fractures only.

In this study, we had a significant incidence of complications, nonunion, stiffness, and residual pain.

The limitation of our study is the small number of cases and lack of correlation between the type of fracture and the results.

From the results, we concluded that proximal humerus fractures in the elderly should be treated operatively as much as possible and conservative treatment roles should be restricted for patients unfit for surgery.

References:

1. DeFranco MJ, Brems JJ, Williams Jr GR, Iannotti JP. Evaluation and management of valgus impacted four-part proximal humerus fractures. *Clinical Orthopaedics and Related Research* (1976-2007). 2006;442:109-14.
2. Twiss T. Nonoperative treatment of proximal humerus fractures. *Proximal Humerus Fractures*: Springer; 2015:23-41.
3. Court-Brown CM, Garg A, McQueen MM. The epidemiology of proximal humeral fractures. *Acta orthopaedica Scandinavica*. 2001;72(4):365-71.
4. Doetsch A, Faber J, Lynnerup N, Wätjen I, Bliddal H, Danneskiold-Samsøe B. The effect of calcium and vitamin D 3 supplementation on the healing of the proximal humerus fracture: a randomized placebo-controlled study. *Calcified tissue international*. 2004;75(3):183-8.
5. Palvanen M, Kannus P, Niemi S, Parkkari J. Update in the epidemiology of proximal humeral fractures. *Clinical Orthopaedics and Related Research*. 2006;442:87-92.
6. Matsen F. *Glenohumeral Instability. The Shoulder*, fourth edition. Edited by Rockwood CA, Matsen Wirth MA, Lippitt SB. Elsevier; 2009.
7. Zyto K, Ahrengart L, Sperber A, Törnkvist H. Treatment of displaced proximal humeral fractures in elderly patients. *The Journal of bone and joint*

- surgery. British volume. Related Research. 2011;469(12):3292-9.
1997;79(3):412-7.
8. Koval KJ, Gallagher MA, Marsicano JG, Cuomo F, McShinawy A, Zuckerman J. Functional outcome after minimally displaced fractures of the proximal part of the humerus. *JBJS*. 1997;79(2):203-7.
9. Ong C, Bechtel C, Walsh M, Zuckerman JD, Egol KA. Three-and four-part fractures have poorer function than one-part proximal humerus fractures. *Clinical Orthopaedics and*
10. Hanson B, Neidenbach P, de Boer P, Stengel D. Functional outcomes after nonoperative management of fractures of the proximal humerus. *Journal of Shoulder and Elbow Surgery*. 2009;18(4):612-21.
11. Caceres E, Torrens C, Corrales M, Vila G, Santana F. Functional and quality of life results of displaced and nondisplaced proximal humeral fractures treated conservatively. *Journal of Orthopaedic Trauma* 2011;25(10):581-7