



# One-stage versus Two-stage Repair of Hypospadias with Marked Chordae: A Non-Randomized Comparative Study

Hazem Mohamed El Moghazy<sup>1</sup>, Mohamed Faisal Abd El Latif<sup>1</sup>, Ahmed Rashid Hamady<sup>1</sup>, Mohamed Mustafa Hussein<sup>2</sup>.

- 1- Urology department, faculty of medicine, Sohag University
- 2- Urology department, faculty of medicine, Aswan university

## Abstract

**Purpose:** The one-stage repair offers the benefit of utilizing skin that prior surgical operations have not damaged, has an intact blood supply and requires fewer hospitalization days, but it also depends on the surgeon's "expertise" and the family's preferences. Two-stage surgery is frequently preferred in severe primary proximal hypospadias or revision hypospadias. This study aimed to compare the surgical and functional outcomes of one-stage vs. two-stage hypospadias chordal repair.

**Methods:** We conducted a comparative, non-randomized, prospective study on 60 patients with hypospadias with any degree of marked chordae. Patients were allocated to receive either one-stage or two-stage repair using onlay grafts and flaps. All patients were followed for one year postoperatively. The repair was completed six months later using the standard Thiersch–Duplay technique in those with a two-stage repair.

**Results:** Thirty patients were managed in a two-stage procedure (28 with onlay preputial flap and two with buccal mucosal graft), while the remaining 30 patients were managed with a single-stage hypospadias repair with preputial skin flap (tabularized or onlay). The blood loss and operative time were significantly higher in the two-stage procedure group ( $p < 0.05$ ). The success rate of surgery in the one-stage group was 80%, while the two-stage group had a success rate of 83%, indicating a statistically insignificant difference between the two groups. The postoperative complication rate was 20% and 17% in the one-stage and two-stage groups, respectively.

**Conclusion:** The one-stage correction is an effective surgical procedure for treating this condition, with short operative time and less blood loss without the need for a second stage.

**Keywords:** Hypospadias; Marked Chordae; One-stage Repair; Two-stage Repair.

**DOI:** 10.21608/smj.2023.218719.1396

## Introduction:

Hypospadias is considered one of the most frequent congenital anomalies in males, with a frequency of one in every 300 live births.<sup>(1)</sup> Historically, hypospadias was considered an isolated anomaly, but recent investigations have shown that it may be linked to severe urological, genetic, hormonal, and extra-urological problems.<sup>(2)</sup> It has been found that an undescended testicle is the most prevalent related abnormality in around 3% of children with proximal and 10% of children with distal hypospadias.<sup>(3,4)</sup> In

the past 30 years, many new procedures and methods have been developed to provide better cosmetic results with fewer complications.<sup>(5,6)</sup> The current hypospadias surgical objectives are to achieve symmetry in the look of the glans and shaft, create a urethra of suitable and consistent diameter, normalize erections and voiding, place the meatus on the penile tip, and create a straight penis.<sup>(7)</sup>

Following hypospadias repair, postoperative complications range from 24 percent in the first

year following surgery to 60 percent in long-term follow-up. <sup>(8)</sup> Hypospadias repair may begin at three months of age in healthy, full-term newborns. Surgery on premature newborns is often performed at six months of age or older. Chord correction, urethroplasty, and penis reconstruction are the three primary stages of hypospadias surgery. <sup>(9,10)</sup> The one-stage repair offers the benefit of utilizing skin that prior surgical operations have not damaged, has an intact blood supply, and requires fewer hospitalization days. Still, it also depends on the surgeon's "expertise" and the preferences of the family. <sup>(11)</sup> On the other hand, it is often linked to re-interventions to address complications and poor aesthetic outcomes in severe cases. Two-stage surgery is frequently preferred in severe primary proximal hypospadias or revision hypospadias. <sup>(12)</sup> This study aimed to compare the surgical and functional outcomes of one-stage vs. two-stage hypospadias chordal repair.

### **The outcomes of the study:**

- The primary outcome was to assess the "success rate" between the two study groups.
- The secondary outcome was to compare the "operative details" between the two groups (for e.g. operative time and blood loss) and the complications of the two operations (early and late complications).

### **Materials and Methods:**

The present manuscript was prepared in concordance with the recommendations of the STROBE Statement. <sup>(13)</sup> The study's protocol was approved and registered by the local ethics committee of Sohag University Teaching Hospitals. The details of the procedure were discussed with the parents including advantages, disadvantages, and complications of the procedure. Parents of eligible patients signed written informed consent before study enrollment.

### **Study Design and Patients:**

We conducted a comparative, non-randomized, prospective study on 60 patients with hypospadias with any degree with marked chordae from the period between April 2017 and April 2018. We excluded patients with a history of repeated

hypospadias repair or curvature without hypospadias. Patients were allocated to receive either one-stage or two-stage repair using onlay grafts and flaps. All patients were followed for one year postoperatively. In those with a two-stage repair, the repair was completed six months later using the standard Thiersch–Duplay technique. All children were assessed preoperatively for demographic characteristics, examination of flans penis and prepuce, chordee characteristics, presence of rotation, position, site of the meatus, and associated anomalies. Besides, all patients underwent routine laboratory assessment and were admitted one day before the procedure to receive prophylactic 3<sup>rd</sup> generation cephalosporin.

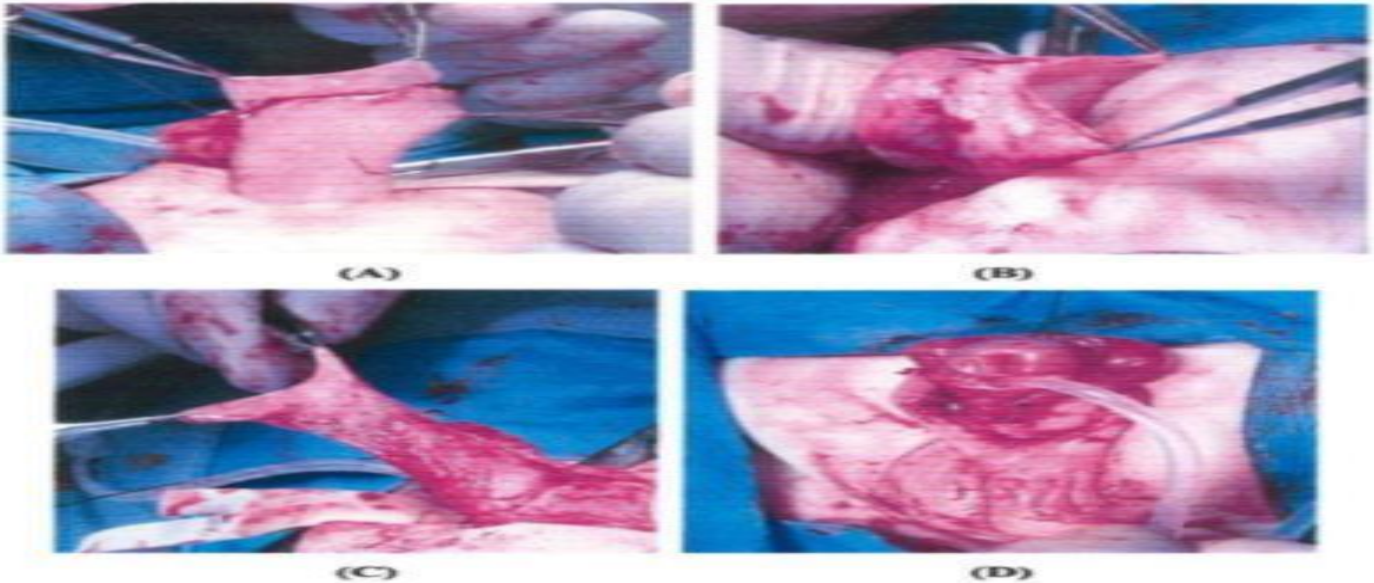
### **Operative Technique**

All procedures were performed under general anesthesia, with caudal analgesia, while the patients were supine. We utilized several tissue transfer techniques (preputial skin/buccal mucosa grafts and onlay preputial flaps) for repair depending on the availability and surgeon's decision. In all procedures, we executed traction suture on the glans penis tip, followed by circumferential incision on the penis ventrum bilateral to the plate close to the meatus. For residual chordee, either Nesbit ellipses excision or dorsal plication of tunica albuginea was performed. Then, the urethral plate was fixed to the glans penis tip by interrupted 7-0 Vicryl suture. In the preputial skin and buccal mucosa grafts procedures, a graft from the inner leaf of the prepuce or buccal mucosal graft was harvested (**Figure 1 and 2**), respectively. A 10F catheter was introduced to the urethral plate to guide the introduction of the graft and its fixation to the plate. The graft was sutured using a running 7-0 Vicryl suture. An interrupted and running 6-0 Vicryl sutures were used to close the glans and corpus spongiosum, respectively. Then, the prepuce was closed with an interrupted 7-0 Vicryl suture. Finally, we closed the skin with interrupted 5-0 chromic catgut. In the preputial island flap, the flap was harvested from the dorsal foreskin and rotated around the penis over the urethral plate. Then, a pedicle part was used to cover the island flap. An 8F catheter was used for urinary diversion in all

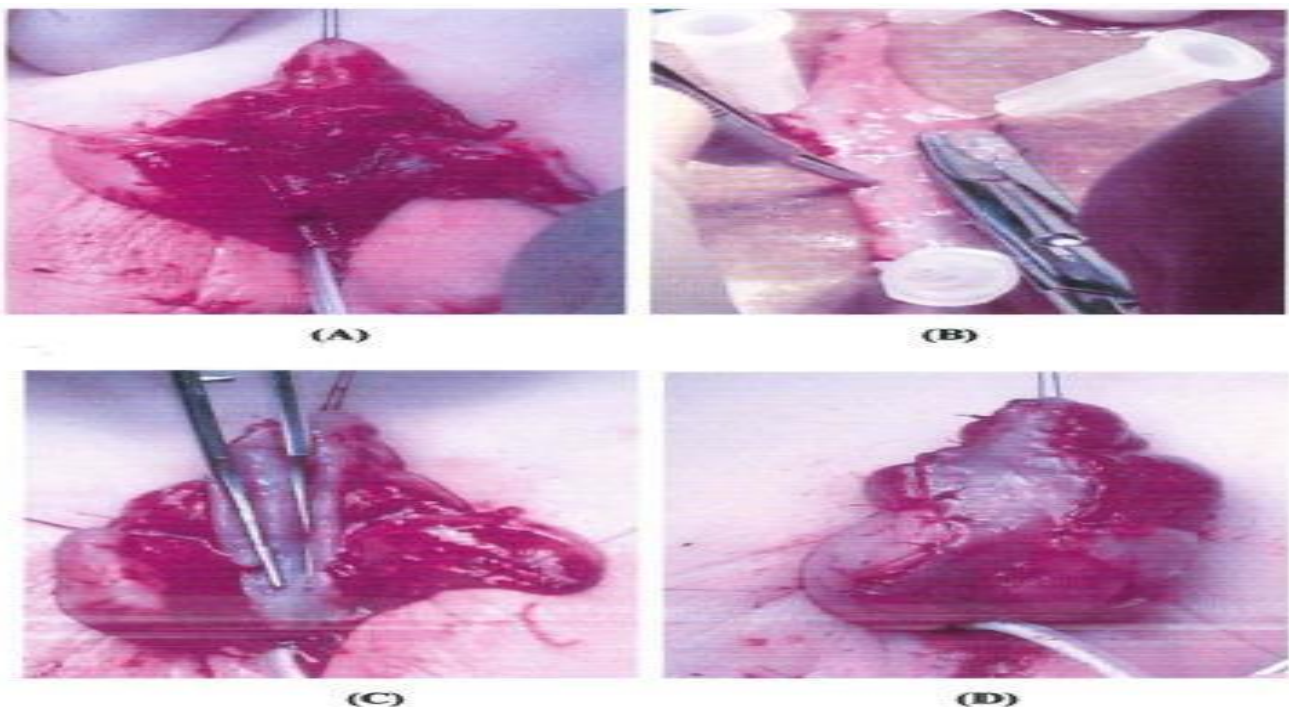
procedures, and a light dressing was used to accomplish compression.

In the two-stage group, a second procedure was performed after six months (**Figure 3**). An extended incision was performed distally for up to 0.2cm lateral to the graft or flap, and glanular wings were established. Then, the urethral strip was tabularized with a continuous 7-0 Vicryl suture over an 8F

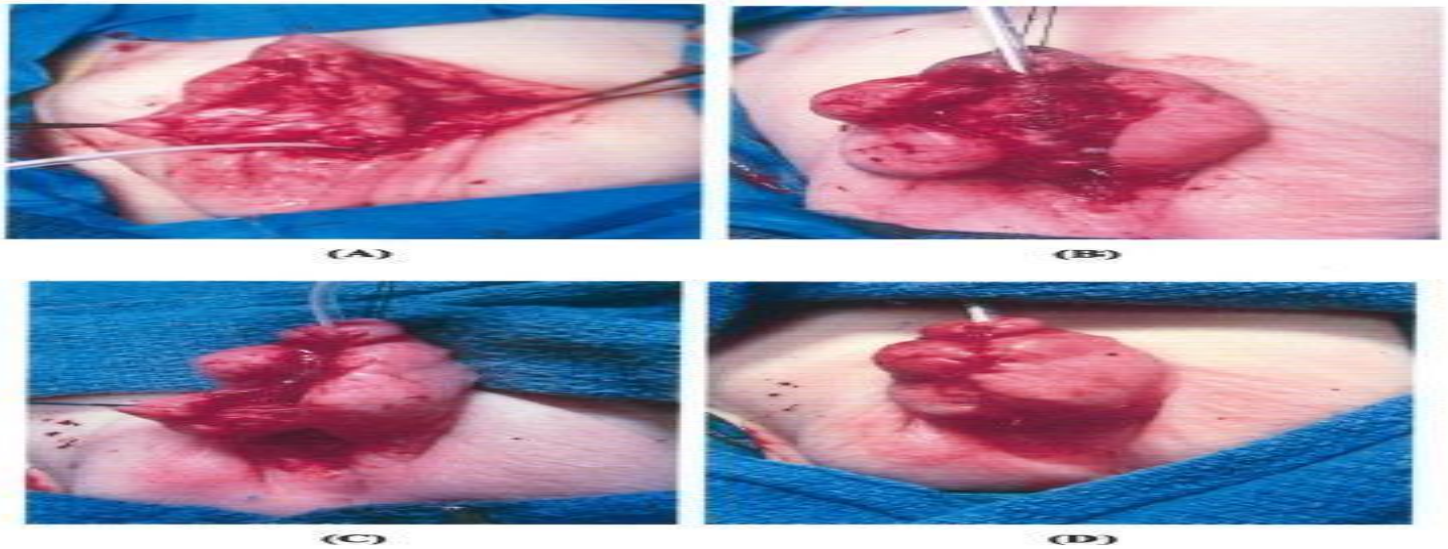
Foley catheter. A second layer (dartos fascia) was developed and sutured with mattress sutures to cover the tabularized urethral plate. The glanular wings were approximated with 6-0 and 7-0 Vicryl sutures. The penile skin was approximated with 5-0 Vicryl Rapide sutures. A pressure dressing was applied.



**Fig. (1):** Onlay preputial island flap (A-D).



**Fig. (2):** First stage buccal mucosal graft urethroplasty (A-D). A. Urethral bed ready to receive the graft. B. Buccal mucosal graft pinned onto cardboard for defatting and trimming (in vitro). C&D. Buccal mucosal graft fixed ventrally in the first stage.



**Fig. (3):** Second stage Buccal mucosal graft urethroplasty (A-D). A. Urethral plate (Buccal mucosal graft) outlined. B. Tubularization of Buccal mucosal graft. C. Intermediate layer closure (dartos). D. Skin closure.

**Statistical Analysis:**

All statistical analyses were performed using SPSS version 22.0 for Windows. Continuous data were expressed as mean ( $\pm$  standard deviation [SD]), and categorical data were described as percentages. The association between the type of membrane coverage and perioperative characteristics was tested using the Chi-square test, with a p-value  $<0.05$  denoting statistical significance.

**Results:**

Thirty patients were managed in a two-stage procedure (28 with onlay preputial flap and two with buccal mucosal graft), while the remaining 30 patients were managed with a single-stage hypospadias repair with a preputial skin flap (tabularized or onlay).

The mean age was  $5.5 \pm 0.9$  years for the one-stage group and  $5.3 \pm 0.8$  years for the two-stage group (Table 1).

**Table 1: demographic data of the study groups**

	Group A	Group B	P value
Number of cases	30	30	
Age of study groups	$5.5 \pm 0.9$	$5.3 \pm 0.8$	$>0.05$

As regard types of hypospadias, about 12 patients (20%) were presented with distal penile hypospadias, 19 patients (31%) were presented with mid-penile hypospadias, 16 (26%) were presented with PPH, ten patients with penoscrotal hypospadias (16%), and three patients (5%) with scrotal hypospadias.

Chordae was corrected by complete penile degloving in 19 patients (32%), midline dorsal plication of tunica albuginea in 7 (11.7%), excision of Nesbit ellipses in 25 (41.6%), and urethral plate mobilization and excision in nine patients (15%). Persistent chordae was encountered in one patient. In our study, six patients had a previous history of

cryptorchidism (9%). Of them, four patients were managed with inguinal orchiolysis and orchiopexy first, then three months later, and then hypospadias repair. Penile torsion was encountered in 12 patients (19.5%) and was corrected by penile degloving. Penoscrotal transposition was encountered in two patients (3%) with penoscrotal hypospadias and scrotal hypospadias in one patient. All were managed with the excision of elliptical rugal skin cranial to the penoscrotal junction. Small-sized penis was encountered in five patients.

The rate of blood loss was significantly higher in the two-stage procedure than in the one-stage procedure. Regarding the operative time comparison between the two groups, we found that the mean operative time for the one-stage procedure was 118±5 minutes and 250±5 minutes for the two-stage procedure. The postoperative complication rate was 20% and 17% in the one-stage and two-stage groups, respectively. In the one-stage group,

there were six cases with urinary fistula (four in the shaft and two in the coronal sulcus), one case of glanular dehiscence, one case with repair breakdown, two cases with meatal stenosis, and one with persistent chordee. Among these cases, six were treated by performing fistula repair, urethroplasty, or dorsal meatotomy.

In contrast, three patients with urinary fistula did not receive a second surgery after declining the urinary fistula with follow-up. One patient with meatal stenosis improved with frequent dilatation and one with persistent chordae less than 30 degrees. In the two-stage group, five patients reported urinary fistula. Only three of these cases required reoperation. One case with repair breakdown was successfully repaired after reoperation and another three patients with meatal stenosis. Only one of these cases was repaired with dorsal meatotomy (**Table 2**).

**Table 2: Comparison of the intra and postoperative data**

Variables		One-stage (n =30)	Two-stage (n = 30)	P-value
<b>Blood loss (mg)</b>	Mean ±SD	5+2	10+2	0.05
<b>Operative time (minutes)</b>	Mean ±SD	118±5	200±5	0.05
<b>Early Complications</b>	Hematoma	4 (13.3%)	2 (6.7%)	>0.05
	Catheter slippage	2 (6.7%)	2 (6.7%)	>0.05
	Catheter blockage	2 (6.7%)	2 (6.7%)	>0.05
	Infection	2 (6.7%)	1 (3.3%)	>0.05
	Fistula	6 (20%)	5 (16.7%)	>0.05
	Glans dehiscence	1 (3.3%)	0	>0.05
	Repair breakdown	1 (3.3%)	1 (3.3%)	>0.05
<b>Late Complications</b>	Meatal stenosis	2 (6.7%)	3 (10%)	>0.05
	Stricture	0	0	0
	Diverticula	0	0	0
	Persistent chordae	1 (3.3%)	0	0
	Reoperation	6 (20%)	5 (16.7%)	>0.05
	Meatal stenosis	2 (6.7%)	3 (10%)	>0.05
<b>Success rate</b>		24 (80%)	25 (83%)	>0.05

### Discussion:

The treatment of severe hypospadias has been controversial for the last ten years.<sup>(14,15)</sup> The optimum approach to proximal hypospadias is a matter of debate. Many procedures for hypospadias repair have been described, indicating the difficulties in achieving optimal outcomes from this

kind of surgery.<sup>(16)</sup> Although one-stage repair is effective in certain cases with proximal hypospadias,<sup>(17,18)</sup> many surgeons still prefer a staged approach when moderate to severe chordee is present to obtain appropriate straightening and

lengthening of the penis at the time of the first-stage surgery. <sup>(18-21)</sup>

Using a large series of hypospadias patients with marked chordae, we compare the results of a single-stage hypospadias treatment with those of a two-stage hypospadias repair. Patients with hypospadias ranging from mild to severe were included in the study. The mean operative time was significantly ( $p < 0.05$ ) higher in the two-stage operation than in the single-stage operation. Blood loss was significantly ( $p < 0.05$ ) higher in two-stage operations than in single-stage operations. The overall complication rate was 20% in the one-stage operation and 17% in events in the two-stage operation; however, there was no significant difference between both groups ( $p > 0.05$ ). The most common early complication reported in our population were fistula, hematoma, catheter slippage, catheter blockage, and infection. Regarding the late complications, metal stenosis and persistent chordee were also reported. Reoperation was reported in six patients and five patients in the one- and two-stage operations, respectively. Additionally, age at time of the surgery, the diameter of the glans penis, and length of the urethral defect failed to show any statistically significant difference between the one-stage and two-stage groups. No urethral stricture was found in either group. No statistically significant difference was found in the incidence of the urethral diverticulum or granular dehiscence. The overall success rate was high ( $\geq 80\%$ ) and comparable in both groups ( $p > 0.05$ ).

Gozar et al. evaluated 10 hypospadias patients with severe chordee and very thin Ventral skin. Our findings are consistent with those of Gozar et al. <sup>(22)</sup> The One-stage lateral-based flap method was used to treat all patients mainly. The average operative time was 2 hrs and 30 minutes. There were no difficulties during the surgery, and the edema after the procedure was mild. All 10 patients had satisfactory outcomes, with normal voiding, straight penis, and orthotopic glanular meatus in eight patients. The other two patients had a urethrocutaneous fistula at the level of the former meatus without associated stenosis after surgery.

During the two-year follow-up period, no cosmetic disorders were discovered. <sup>(22)</sup>

Twenty-one hypospadias patients with severe chordee were investigated by Chen and colleagues in 2006. The One-stage approach was mainly used to correct all patients. Nineteen of the twenty-one patients (90%) had positive outcomes. The other two patients had developed urethrocutaneous fistulas after their operations (10%). <sup>(23)</sup> There were 107 hypospadias children with severe chordee evaluated by Hadidi et al. in 2008. One-stage urethroplasty is used by all patients. Ninety-seven patients (91%) out of a total of 107 had positive outcomes. Ninety-seven patients out of a total of 107 had positive outcomes or 91%. Another 10 patients had surgical complications, including urethrocutaneous fistula (3%), urethral stenosis (2%), and diverticulum (1%). <sup>(24)</sup> Patients in our study were older than those in the Hadidi et al Study, which may have contributed to the greater complication rate. In comparison, just three patients in the two-stage group needed reoperation for urinary fistula.

Zheng et al. conducted a retrospective study of 34 patients with hypospadias with marked chordae who underwent two-stage urethroplasty. They found postoperative complications in the form of urethrocutaneous fistula in 7 patients, meatal stenosis in one patient, and dehiscence and infection in one patient. This study had a complication rate of 26%, which may have been because the individuals in this trial were older than those in previous studies (ranging from 2 to 43 years). <sup>(25)</sup>

Proximal hypospadias with marked chordae was seen in 43 patients who had two-stage urethroplasty, with a 23% complication risk for the procedure, according to Snodgrass W and Bush N. <sup>(26)</sup> Johal et al. investigated 62 patients with proximal and midshaft hypospadias and prominent chordae, all of whom were mainly treated with two-stage urethroplasty, with an 18% complication rate. <sup>(27)</sup> A single-stage procedure would not have the same postoperative problems as a two-stage operation; single-stage surgery may minimize the number of operations to only one and so reduces patient burden and pain. <sup>(28)</sup>

Transverse preputial on lay island flap urethroplasty for single-stage repair was shown to provide reliable functional outcomes in 136 patients with proximal hypospadias by Singal AK et al.<sup>(29)</sup> One-stage surgery for the treatment of proximal hypospadias is preferred by Emir H. et al. because it provides better outcomes and better patient satisfaction.<sup>(30)</sup> When proximal hypospadias surgery was compared to two-stage surgery, Castagnetti M et al. showed that the overall incidence of postoperative complications was not higher than the single-stage procedure.<sup>(31)</sup>

In conclusion, hypospadias with marked chordae is a serious condition, and the single-stage correction is an effective surgical procedure for treating this condition, with short operative time and less blood loss without the need for a second stage. The postoperative complications of single-stage surgery were comparable to those of two-stage surgery. The main limitation of the two-step technique is the second operation, which has a negative psychosocial effect on the patient and his family. More care should be given to preserving the blood supply of the vascular pedicle in the foreskin during the procedure, as well as fully repairing chordae. It is also necessary to improve the usage of postoperative care and disinfection.

#### **Conflict of interest:**

All authors confirm no financial or personal relationship with a third party whose interests could be positively or negatively influenced by the article's content.

#### **Funding source:**

None (authors confirm they did not receive any funding to do this work)

#### **References:**

1. Baskin LS, Ebbers MB. Hypospadias: anatomy, etiology, and technique. *J Pediatr Surg.* Elsevier; 2006;41:463–72.
2. Santangelo K, Rushton HG, Belman AB. Outcome analysis of simple and complex urethrocutaneous fistula closure using a de-epithelialized or full-thickness skin advancement flap for coverage. *J Urol.* United States; 2003;170:1589–92; discussion 1592.
3. Aigrain Y, Cheikhelard A, Lottmann H, Lortat-Jacob S. Hypospadias: surgery and complications. *Horm Res Paediatr.* Switzerland; 2010;74:218–22.
4. Sunay M, Dadali M, Karabulut A, Emir L, Erol D. Our 23-year experience in urethrocutaneous fistulas developing after hypospadias surgery. *Urology.* United States; 2007;69:366–8.
5. Shankar KR, Losty PD, Hopper M, Wong L, Rickwood AMK. Outcome of hypospadias fistula repair. *BJU Int.* England; 2002;89:103–5.
6. Hosseini J, Kaviani A, Mohammad Hosseini M, Rezaei A, Rezaei I, Javanmard B. Fistula repair after hypospadias surgery using buccal mucosal graft. *Urol J.* Iran; 2009;6:19–22.
7. Routh JC, Wolpert JJ, Reinberg Y. Tunneled tunica vaginalis flap for recurrent urethrocutaneous fistulae. *Adv Urol.* 2008;2008:615928.
8. Cimador M, Castagnetti M, De Grazia E. Urethrocutaneous fistula repair after hypospadias surgery. *BJU Int.* England; 2003;92:621–3.
9. Richter F, Pinto P, Stock J, Hanna M. Management of recurrent urethral fistulas after hypospadias repair. *Urology.* 2003;61:448–51.
10. Kajbafzadeh A-M, Abolghasemi H, Eshghi P, Alizadeh F, Elmi A, Shafaattalab S, et al. Single-donor fibrin sealant for repair of urethrocutaneous fistulae following multiple hypospadias and epispadias repairs. *J Pediatr Urol.* England; 2011;7:422–7.
11. Ambriz-González G, Velázquez-Ramírez GA, García-González JL, de León-Gómez JMG, Muciño-Hernández MI, González-Ojeda A, et al. Use of fibrin sealant in hypospadias surgical repair reduces the frequency of postoperative complications. *Urol Int.* Switzerland; 2007;78:37–41.
12. Gopal SC, Gangopadhyay AN, Mohan TV, Upadhyaya VD, Pandey A, Upadhyaya A, et al. Use of fibrin glue in preventing urethrocutaneous fistula after hypospadias repair. *J Pediatr Surg.* United States; 2008;43:1869–72.
13. Schulz KF, Altman DG, Moher D, Barbour V, Berlin JA, Boutron I, et al. CONSORT 2010 statement: Updated guidelines for reporting parallel

- group randomised trials (Chinese version). *J Chinese Integr Med.* 2010;8:604–12.
14. Dohan DM, Choukroun J, Diss A, Dohan SL, Dohan AJJ, Mouhyi J, et al. Platelet-rich fibrin (PRF): a second-generation platelet concentrate. Part I: technological concepts and Evolution. *Oral Surg Oral Med Oral Pathol Oral Radiol Endod.* United States; 2006;101:e37-44.
  15. Dohan Ehrenfest DM, Del Corso M, Diss A, Mouhyi J, Charrier J-B. Three-dimensional architecture and cell composition of a Choukroun's platelet-rich fibrin clot and membrane. *J Periodontol.* United States; 2010;81:546–55.
  16. Dohan DM, Choukroun J, Diss A, Dohan SL, Dohan AJJ, Mouhyi J, et al. Platelet-rich fibrin (PRF): a second-generation platelet concentrate. Part II: platelet-related biologic features. *Oral Surg Oral Med Oral Pathol Oral Radiol Endod.* United States; 2006;101:e45-50.
  17. Choukroun J, Diss A, Simonpieri A, Girard M-O, Schoeffler C, Dohan SL, et al. Platelet-rich fibrin (PRF): a second-generation platelet concentrate. Part IV: clinical effects on tissue healing. *Oral Surg Oral Med Oral Pathol Oral Radiol Endod.* United States; 2006;101:e56-60.
  18. Choukroun J, Diss A, Simonpieri A, Girard M-O, Schoeffler C, Dohan SL, et al. Platelet-rich fibrin (PRF): a second-generation platelet concentrate. Part V: histologic evaluations of PRF effects on bone allograft maturation in sinus lift. *Oral Surg Oral Med Oral Pathol Oral Radiol Endod.* United States; 2006;101:299–303.
  19. Soyer T, Çakmak M, Aslan MK, Şenyücel MF, Kisa Ü. Use of autologous platelet-rich fibrin in urethrocutaneous fistula repair: a preliminary report. *Int Wound J.* 2013;10:345–7.
  20. Hick EJ, Morey AF. Initial experience with fibrin sealant in pendulous urethral reconstruction. Is early catheter removal possible? *J Urol.* United States; 2004;171:1547–9.
  21. Kinahan TJ, Johnson HW. Tisseel in hypospadias repair. *Can J Surg. Canada;* 1992;35:75–7.
  22. Gozar, H., Ardelean, M., & Gurzu, S. One-stage repair of proximal hypospadias using lateral penile flapper preliminary results in a single-centre experience. *The Indian journal of surgery;* 2014;76(2):171–173.
  23. Chen W, Li S, Li Y, Yang M, Li Q, [One stage repair of hypospadias using meatal-based flap overlapping with buccal mucosal graft], *Zhongguo Xiu Fu Chong Jian Wai Ke Za Zhi* 2006;20(3):220-2.
  24. Hadidi AT, Azury AF. *Hypospadias surgery: an illustrated guide.* Springer, Berlin. 2004.
  25. Zheng D-C, Yao H-J, Cai Z-K, Da J, Chen Q, Chen Y-B, et al., Two-stage urethroplasty is a better choice for proximal hypospadias with severe chordee after urethral plate transection: a single-centre experience, *Asian journal of andrology* 2015;17(1):94
  26. Snodgrass W, Bush N, Staged Tubularized Autograft Repair for Primary Proximal Hypospadias with 30-Degree or Greater Ventral Curvature, *The Journal of Urology* 2017;198(3):680-686.
  27. Johal NS, Nitkunan T, O'Malley K, Cuckow PM, The two-stage repair for severe primary hypospadias, *European urology* 2006;50(2):366-71.
  28. Cui X, He Y, Huang W, Chen L, Wang Y, Zhou C, Clinical efficacy of transverse preputial island flap urethroplasty for single-stage correction of proximal hypospadias: a single-centre experience in Chinese patients, *BMC Urol* 2020;20(1):118.
  29. Singal AK, Dubey M, Jain V. Transverse preputial onlay island flap urethroplasty for single-stage correction of proximal hypospadias. *World J, Urol.* 2016;34(7):1019–24.
  30. Emir H, Jayanthi VR, Nitahara K, Danismend N, Koff SA. Modification of the Koyanagi technique for the single-stage repair of proximal hypospadias. *J Urol.* 2000;164(3 Pt 2):973–5.
  31. Castagnetti M, Zhapa E, Rigamonti W. Primary severe hypospadias: comparison of reoperation rates and parental perception of urinary symptoms and cosmetic outcomes among 4 repairs. *J Urol.* 2013; 189(4):1508–13.